

Aplastic Anemia Following COVID-19 Vaccination: A Systematic Review of Case Reports and Case Series

Nelson Luis Cahuapaza-Gutierrez^{1,2}, Tsurriel Sofía Campos-Escalante¹

¹Facultad de Ciencias de la Salud, Carrera de Medicina Humana, Universidad Científica Del Sur, Lima, Perú

²Change Research Working Group, Universidad Científica del Sur, Lima, Perú

Corresponding Author: Nelson Luis Cahuapaza-Gutierrez, Facultad de Ciencias de la Salud, Carrera de Medicina Humana, Universidad Científica Del Sur, Lima, Perú

E-mail: 100065659@cientifica.edu.pe

Received: 06, May, 2023

Accepted: 23, Dec, 2023

ABSTRACT

Aplastic anemia (AA) is the prototypical bone marrow failure syndrome due to a destruction of hematopoietic stem cells by cytotoxic T cells. According to case reports, vaccines could lead to the development of AA. We conducted the present systematic review to evaluate cases of AA following vaccination against coronavirus disease (COVID-19).

We searched the following databases: PubMed, Scopus and EMBASE in English, Portuguese, and Spanish languages until April 24, 2023. Published reports and case series on the occurrence of AA following vaccination against COVID-19 were included. The Joanna Brigs Institute was used to assess study quality and risk of bias. Six studies were selected from 102 research studies and data were extracted according to the inclusion criteria. All case reports and case series reported the occurrence of AA following COVID-19 vaccination. AA events were mainly observed in vaccines with messenger ribonucleic acid technology (Moderna; Pfizer-BioNTech). AA was diagnosed by bone marrow biopsy and severity was determined by Camitta criteria.

All cases of AA were properly diagnosed. The sample size was small; therefore, further investigations are required to demonstrate and elucidate the complete pathophysiological mechanisms of AA development after receiving COVID-19 vaccination.

Keywords: Anemia; Aplastic; Aplastic anemia; COVID-19 Vaccines; SARS-CoV-2 Vaccines

INTRODUCTION

Aplastic anemia (AA) is a rare hematologic disorder presenting as a bone marrow failure syndrome¹. It has an estimated incidence in Europe and the USA of 2 to 3 cases/million and 5 to 6 cases/million in Asia, with a bimodal distribution for age between 15-25 years and over 60 years, with no gender and race differences².

The etiology of AA is diverse, it is associated with occupational exposure to haptens such as benzene and pesticides, exposure to drugs, such as

chloramphenicol and antiepileptics, among others that are reported³. AA is also associated with pregnancy, although it is a rare condition, but if left untreated it can cause severe maternal and fetal complications⁴. Other causes include AA associated with hepatitis, viral infections, radiation, and autoimmune disorders⁵. In most cases of AA, the cause is unknown, so it is called idiopathic AA⁶.

Acquired AA is immune mediated by cytotoxic T cells that destroy and suppress hematopoietic progenitor cells. Hereditary AA is caused by various germline

Copyright © 2024 Tehran University of Medical Sciences. This work is licensed under a Creative Commons Attribution-Noncommercial 4.0 International license (<http://creativecommons.org/licenses/by-nc/4.0>). Non-commercial uses of the work are permitted, provided the original work is properly cited.

mutations involving alterations in DNA repair, telomere maintenance or hematopoiesis⁷. Patients with AA usually have anemia, thrombocytopenia and infections resulting from autoimmune destruction. A hemoglobin (Hb) concentration <100 g/L, platelet count (PLT) <50 × 10⁹ /L, neutrophil count (ANC) <1.5 × 10⁹ /L must be present for the diagnosis of AA. The Camitta criteria are used to assess the severity of AA and divides it into three groups: non-severe AA (NSAA), severe AA (SAA) and very severe AA (VSAA)⁸. Treatment for AA is based on immunosuppressive therapy (IST) (anti-thymocyte globulin (ATG) and cyclosporin A (CsA)) or stem cell transplantation. IST has a hematologic response rate of about 60 to 65%. However, the addition of a thrombopoietin agonist, eltrombopag (EPAG) improves the response⁹. Severe acute respiratory syndrome coronavirus 2 (SARS-CoV-2) infection causing coronavirus disease (COVID-19) continues, with new variants spreading rapidly and causing high morbidity and mortality, with more than 763 million diagnosed cases and more than 6.9 million deaths worldwide^{10,11}. Faced with the emerging status for COVID-19, the US Food and Drug Administration (FDA) issued the emerging use of vaccines such as Pfizer-BioNTech (BNT162b2 mRNA), modern (mRNA-1273) and Janssen/Johnson (traditional viral vector)⁹. Currently, existing vaccines against SAR-CoV-2 include inactivated, live attenuated, viral vector, protein subunit, RNA, DNA, and virus-like particle vaccines. The vaccines are intended to elicit T-cell immunity, B-cell immunity, and other immune responses¹². Case reports have reported the occurrence of AA after vaccination against SARS-CoV-2, with a possible relation to the immune response that the vaccines produce¹³⁻¹⁵. AA is suggested as an adverse event after vaccination of special interest, because of this it is important to synthesize the current evidence to have knowledge about this adverse reaction. Therefore, our objective was to perform a systematic review of all published case reports and case series of AA after receiving the COVID-19 vaccine.

MATERIALS AND METHODS

The present systematic review follows the guidelines of "Preferred Reporting Items for Systematic Reviews and Meta-Analyses" (PRISMA)¹⁶.

Review objectives

The main objective of the present systematic review is to clarify the possible relationship of aplastic anemia associated with COVID-19 vaccination.

Search strategy

For the present review, a selective bibliographic search was performed in the following electronic databases: PubMed, Scopus and EMBASE. A search strategy was created with the term "Aplastic anemia" related to the terms "COVID-19 Vaccines" and "SARS-CoV-2 Vaccines" by means of Boolean operands "AND" or "OR". The search was completed with gray literature using the following search string: "Aplastic anemia" AND "COVID-19 Vaccine", in Google Scholar. In addition, the reference list of included articles was manually reviewed to identify additional studies. The search strategy for each database is detailed in Supplementary Material. The search was limited to English, Portuguese, and Spanish. The first search was conducted on April 6, 2023, followed by an additional search on April 24, 2023.

The search strategy follows the guidelines of the "Preferred Reporting Items for Systematic reviews and Meta-Analyses literature search extension" (PRISMA-S)¹⁷.

Criteria for inclusion and exclusion

Case report and case series studies on the occurrence of aplastic anemia following COVID-19 vaccination were included. Systematic review and narrative studies, letters to the editor, animal studies, hypotheses and in vitro studies were excluded. In addition, articles with insufficient data and written in languages other than English, Portuguese and Spanish were excluded.

Study selection

The author (NLCG) downloaded all references from the databases to an EndNote document to remove duplicate items. Then, the author exported all references to the Rayyan QCRI website (<https://rayyan.qcri.org/>). Two authors (NLCG and TSCE) independently screened the titles and abstracts of the references to identify relevant studies that met the inclusion criteria for eligibility. The reviewers then evaluated the selected studies in full text. Any discrepancies between reviewers were resolved by mutual discussion.

Data extraction

Two authors (NLCG and TSCE) extracted the data of interest independently. Any disagreement was resolved by mutual discussion. Extraction was performed using a previously prepared Microsoft Excel sheet. Data such as author's name, year of publication, age, sex, type of vaccine, history, time after vaccination, clinical manifestations, laboratory, biopsy, disease severity, treatment and evolution were extracted. The characteristics of the studies are detailed in **Table 1**.

Quality Evaluation

To assess the quality and risk of bias of the present systematic review, the Joanna Brigs Institute (JBI)¹⁸ was used. All studies were assessed by the NLCG author, and any disagreements were mutually resolved. The JBI presents four available assessment options: "Yes, No, Unclear, and Not applicable". In addition, affirmative responses were summarized from 0 to 8. Articles with a score below 4 are considered low quality and those with a score above 4 are considered high quality. The evaluation of the included studies is detailed in Tables 2 and 3.

RESULTS

Eligible studies

A total of 102 studies were identified. After the elimination of duplicates and evaluated for eligibility, 9 articles were selected. Finally, 7 studies were used in the present systematic review. The study selection process is shown in the PRISMA 2020 flow chart Figure 1.

Characteristics of studies included

Six studies were included for systematic review (5 case reports; 1 case series). Nine patients were included in this analysis. The mean age of patients who developed AA following COVID-19 vaccination was 59.1 years. The gender distribution was (2 females; 7 males). Two patients had a history; the first had Hashimoto's thyroiditis and pneumococcal and influenza vaccination, the second had thalassemia. AA events were mostly observed after receiving the Moderna (mRNA) vaccine (after the first dose, n=1; after the second dose, n=3), followed by the Pfizer BioNTech (mRNA) vaccine (after the first dose, n=1; after the second dose, n=2) and finally the Oxford-AstraZeneca (viral vector) vaccine (after the first dose, n=1; after the second dose, n=1). The onset of symptoms after receiving vaccination was estimated to be mainly 2 weeks (n=4), the minimum time was 1 day and the maximum 1 month. The clinical manifestations reported were bleeding, hematomas, fever, dyspnea, muscle pain, melena, petechiae and asthenia. In relation to laboratory parameters the most affected series was Platelets (PLT) (Range: $1-15 \times 10^9 / l$), followed by hemoglobin (Hb) (Range: 43-112 g/l) and absolute neutrophil count (ANC) (Range: $0-0.99 \times 10^9 / l$). Diagnosis was made by bone marrow biopsy and Hypocellularity (<15%) was observed in all cases. The severity of AA was determined by Camitta criteria with VSAA (n=4), SAA (n=4) and NSAA (n=1). Patients received IST + EPAG (n=4), IST + EPAG + methylprednisolone (n=2), IST (n=1), Alo-HCST (n=1) and CsA alone (n=1). Only one patient after treatment with IST + EPAG + methylprednisolone was switched to HCST. Most patients had a favorable evolution, only 1 was readmitted for neutropenic fever and pneumonia. The characteristics of the studies are detailed in Table 1.

Table 1: Characteristics of reported studies on the development of aplastic anemia after vaccination against SARS-CoV-2

Author	Year of publication	Patient age (years)	Sex	Vaccine type	Background	Symptom onset after vaccination	Clinical manifestations	Laboratory	Bone marrow biopsy	Severity of aplasia (According to Camitta Criteria)	Main treatment	Evolution
Cecchi et al. ¹⁹	2021	76	M	Pfizer-BioNTech (ARNm)	None	1 month after second dose	Asthenia and mucocutaneous bleeding	PLT: $3 \times 10^9 / l$ WBC: $3.7 \times 10^9 / l$ ANC: $0.46 \times 10^9 / l$ Hb: 112 g/l	Hypocellularity 10%	SAA	IST	Unknown
Tabata et al. ¹³	2021	56	M	Pfizer-BioNTech (ARNm)	None	4 days after second dose	Bleeding in oral cavity	PLT: $11 \times 10^9 / l$ WBC: $1.6 \times 10^9 / l$	Hypocellularity	VSAA	Alo-HCST	Favorable
Wang et al. ²⁰	2022	67	F	Modern (ARNm)	Hashimoto's thyroiditis, pneumococcal and seasonal influenza vaccines	2 weeks after second dose	None	PLT: $3 \times 10^9 / l$ WBC: $1.8 \times 10^9 / l$ ANC: $0.31 \times 10^9 / l$ Hb: 45 g/l	Hypocellularity 5%	SAA	IST + EPAG	Favorable
Sridhara et al. ²¹	2022	60	M	Modern (ARNm)	None	1 day after second dose	Hematomas and epistaxis	PLT: $1 \times 10^9 / l$ WBC: $1.2 \times 10^9 / l$ ANC: $0 \times 10^9 / l$ Hb: 80 g/l	Hypocellularity < 5%	VSAA	IST + methylprednisolone + EPAG	Discharged, readmitted two days later for neutropenic fever and pneumonia.
Woo et al. ¹⁴	2022	53	M	Modern (ARNm)	None	2 weeks after first dose	Hematomas and melena	PLT: $2 \times 10^9 / l$ WBC: $1.92 \times 10^9 / l$ ANC: $0.12 \times 10^9 / l$ Hb: 66 g/l	Hypocellularity < 5%	VSAA	IST + EPAG	Favorable
Chen et al. ¹⁵	2022	64	F	Oxford-AstraZeneca (viral vector)	None	5 days after first dose	Petechiae and fever	PLT: $3 \times 10^9 / l$ ANC: $0.99 \times 10^9 / l$ Hb: 78 g/l	Hypocellularity < 3%	VSAA	IST + methylprednisolone + EPAG; HCST	Favorable
		73	M	Modern (ARNm)	None	2 weeks after second dose	Fever, muscular pain, and dyspnea	PLT: $13 \times 10^9 / l$ ANC: $0.499 \times 10^9 / l$ Hb: 79 g/l	Hypocellularity < 5%	SAA	IST + EPAG	Favorable
		64	M	Oxford-AstraZeneca (viral vector)	None	2 weeks after second dose	None	PLT: $15 \times 10^9 / l$ ANC: $0.747 \times 10^9 / l$ Hb: 69 g/l	Hypocellularity 3-5%	NSAA	CsA	Partial response
		19	M	Pfizer-BioNTech (ARNm)	Thalassemia	3 weeks after first dose	Severe dyspnea on exertion	PLT: $11 \times 10^9 / l$ ANC: $0.281 \times 10^9 / l$ Hb: 43 g/l	Hypocellularity 10-15%	SAA	IST + EPAG	Partial response

M: male; F: female; mRNA: messenger ribonucleic acid; PLT: platelets; WBC: white blood cells; ANC: absolute neutrophil count; Hb: hemoglobin; IST: immunosuppressive therapy; Alo-HCST: allogeneic hematopoietic stem cell transplantation; EPAG: eltrombopag; CsA: cyclosporin-A; GAT: antithymocyte globulin; G-CSF: granulocyte colony-stimulating factor; G-CSF: granulocyte colony-stimulating factor. NSAA: non-severe aplastic anemia; SAA: severe aplastic anemia; VSAA: very severe aplastic anemia

Table 2: Quality assessment based on the JBI tool for case reports

	Cecchi et al.	Tabata et al.	Wang et al.	Sridhara et al.	Woo et al.
1. Were patient's demographic characteristics clearly described?	Yes	Yes	Yes	Yes	Yes
2. Was the patient's history clearly described and presented as a timeline?	Yes	Yes	Yes	Yes	Yes
3. Was the current clinical condition	Yes	Yes	Yes	Yes	Yes
4. Were diagnostic tests or assessment methods and the results clearly described?	Yes	Yes	Yes	Yes	Yes
5. Was the intervention(s) or treatment procedure(s) clearly described?	Yes	Yes	Yes	Yes	Yes
6. Was the post-intervention clinical condition clearly described?	Unclear	Yes	Yes	Yes	Yes
7. Were adverse events (harms) or unanticipated events identified and described?	Yes	Yes	Yes	Yes	Yes
8. Does the case report provide takeaway lessons?	Yes	Yes	Yes	Yes	Yes

Table 3: Quality assessment based on the JBI tool for case series

	Chen et al.
1. Were there clear criteria for inclusion in the case series?	Yes
2. Was the condition measured in a standard, reliable way for all participants included in the case series?	Yes
3. Were valid methods used for identification of the condition for all participants included in the case series?	Yes
4. Did the case series have consecutive inclusion of participants?	Yes
5. Did the case series have complete inclusion of participants?	Yes
6. Was there clear reporting of the demographics of the participants in the study?	Yes
7. Was there clear reporting of clinical information of the participants?	Yes
8. Were the outcomes or follow up results of cases clearly reported?	Yes
9. Was there clear reporting of the presenting site(s)/clinic(s) demographic information?	Yes
10. Was statistical analysis appropriate?	Yes
Overall appraisal:	10 out of 10

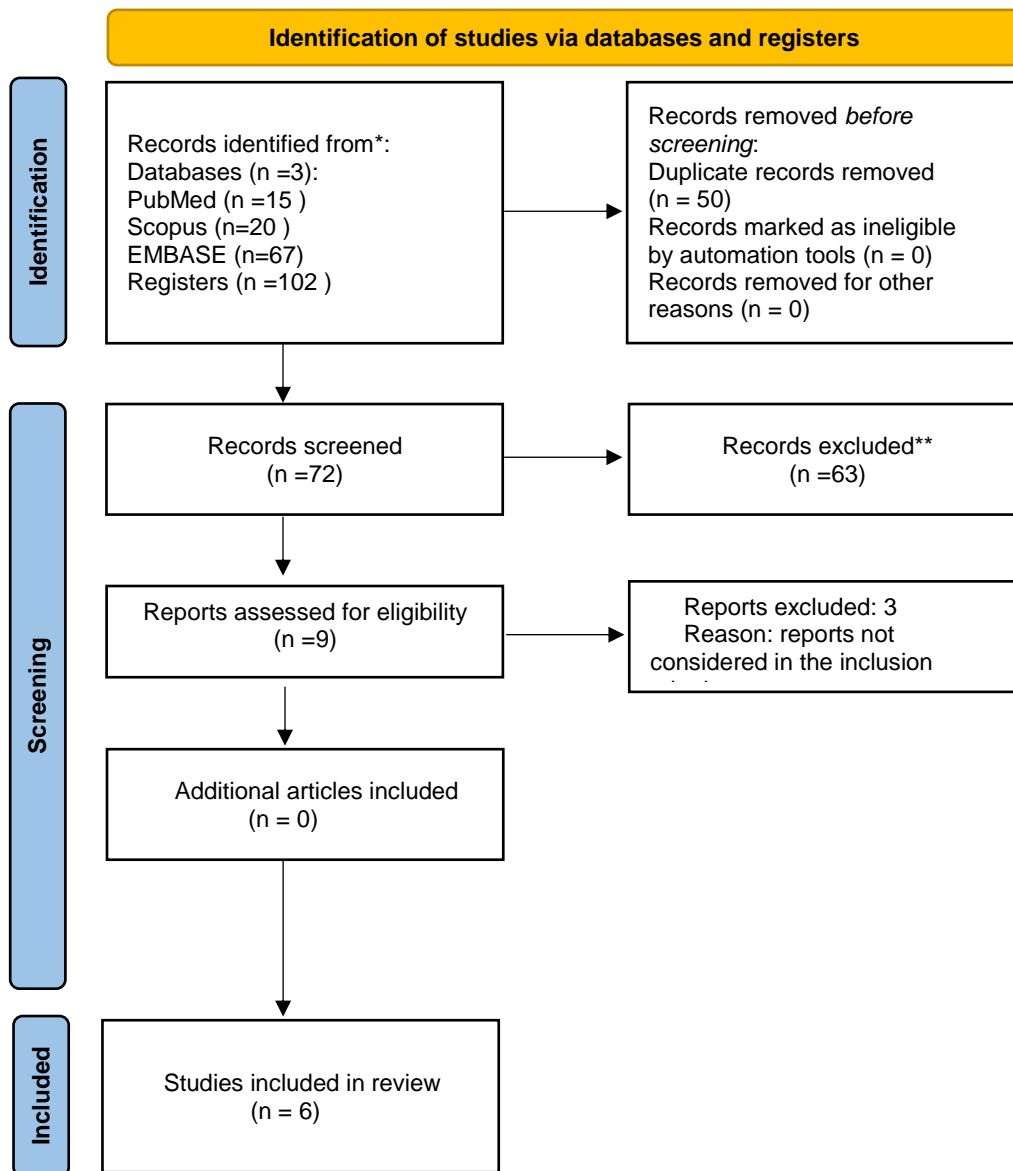


Figure 1. Flow diagram of study selection process for this review

DISCUSSION

Through the present systematic review, we found that vaccination against COVID-19, mainly those with mRNA technology, mainly the Modern vaccine. Most cases occurred in male patients. With severity classification according to SAA and VSAA criteria, only one case reported NSAA. Most of the patients presented a favorable evolution and response to treatment. According to JBI the quality assessment of studies included in this review was of high quality.

Vaccinations and aplastic anemia

The speed of vaccination against COVID-19 generated many concerns in the clinical setting regarding the safety of the various vaccines. Given this, several diseases were reported as complications of vaccination, mainly cardiac complications such as myocarditis, pericarditis, and acute myocardial infarction²². Hematological complications include autoimmune disorders such as immune thrombotic thrombocytopenic purpura, autoimmune hemolytic anemia, Evans syndrome and vaccine-induced thrombotic thrombocytopenia²³⁻²⁶. In addition, very rare diseases such as atypical hemolytic uremic syndrome have been reported²⁷.

The current evidence we have for vaccines is from the various clinical trials. The messenger ribonucleic acid (mRNA) technology vaccines were associated with a higher risk of adverse events. However, in risk/benefit ratio, all types of vaccines outweigh the risks of these vaccines, and it is highly recommended²⁸. Our study showed a relationship with mRNA technology vaccines, mainly Modern. The occurrence of post-vaccination AA is not new. Previously, rare cases have been described in relation to other types of vaccines, such as the occurrence of AA after receiving varicella zoster and H1N1 influenza vaccine^{29,30}. A retro-prospective observational analysis by Röth et al. showed that vaccination against COVID-19 generated relapse in patients with AA who were in stable hematologic remission. The vaccine used was Pfizer-BioNTech (mRNA) and most cases occurred after the second dose³¹.

The main hypotheses involve molecular mimicry. The vaccine could contribute to the pathogenesis of AA¹³. Also, that the underlying immune predisposition

could have allowed the vaccines to trigger a cytotoxic T lymphocyte response producing AA²¹. Another hypothesis posits that the vaccine may induce aberrant T-cell activation¹⁵. All the hypotheses raised could contribute to the development of AA, since in AA there is immune dysregulation by expansion of cytotoxic T cells, decrease in regulatory T cells, and increase in TH-1 inflammation-related cytokines and proteins, particularly interferon- γ (IFN- γ), resulting in destruction of hematopoietic stem cells⁹.

Limitations

Our review has some limitations, which include only the participation of reported case reports and case series. Therefore, the results should be interpreted with some caution. In addition, few studies were included.

CONCLUSION

We systematically evaluated all reported case reports and case series of AA after COVID-19 vaccination. Our systematic review is the first on this pathology of interest and provides an overview of the reported case reports and case series. Nevertheless, further studies are suggested to elucidate the complete pathophysiological mechanisms in relation to the vaccine and the development of AA. In view of the above, comparing the number of reported cases of AA with the number of doses administered and the evolution of the patients. We observe that the benefits of vaccination outweigh the risks. However, it is important to observe and consider the patients mainly in the presence of clinical manifestations suggestive of AA.

CONFLICTS OF INTEREST

The authors declare no conflicts of interest.

REFERENCES

1. Brzeźniakiewicz-Janus K, Rupa-Matysek J, Gil L. Acquired Aplastic Anemia as a Clonal Disorder of Hematopoietic Stem Cells. *Stem Cell Rev Rep*. 2020; 16(3): 472-81.
2. Urbanowicz I, Nahaczewska W, Celuch B. Narrative review of aplastic anemia—the importance of supportive treatment. *Ann Palliat Med*. 2021; 10(1): 69499-699.
3. Shallis RM, Ahmad R, Zeidan AM. Aplastic anemia: Etiology, molecular pathogenesis, and emerging concepts. *Eur J Haematol*. 2018; 101(6): 711-20.
4. Jaime-Pérez JC, González-Treviño M, Gómez-Almaguer D. Pregnancy-associated aplastic anemia: a case-based review. *Expert Rev Hematol*. 2021; 14(2): 175-84.
5. Sweeney R, Esmail F, Mirza KM, Nand S. Hypercellular bone marrow in aplastic anemia: A case report of two patients. *Clin Case Rep*. 2021; 9(11): e04845.
6. Durrani J, Maciejewski JP. Idiopathic aplastic anemia vs hypocellular myelodysplastic syndrome. *Hematol Am Soc Hematol Educ Program*. 2019; 2019(1): 97-104.
7. Giudice V, Selleri C. Aplastic anemia: Pathophysiology. *Semin Hematol*. 2022; 59(1): 13-20.
8. Killick SB, Bown N, Cavenagh J, Dokal I, Foukaneli T, Hill A, et al. Guidelines for the diagnosis and management of adult aplastic anaemia. *Br J Haematol*. 2016; 172(2): 187-207.
9. Patel BA, Townsley DM, Scheinberg P. Immunosuppressive therapy in severe aplastic anemia. *Semin Hematol*. 2022; 59(1): 21-9.
10. WHO Coronavirus (COVID-19) Dashboard. Geneva: World Health Organization; 2023 [accessed 3 April 2023]. Available at: <https://covid19.who.int>.
11. Li M, Wang H, Tian L, Pang Z, Yang Q, Huang T, et al. COVID-19 vaccine development: milestones, lessons and prospects. *Signal Transduct Target Ther*. 2022; 7: 146.
12. Ajmera K, Bansal R, Wilkinson H, Goyal L. Gastrointestinal Complications of COVID-19 Vaccines. *Cureus*. 2022; 14(4): e24070.
13. Tabata S, Hosoi H, Murata S, Takeda S, Mushino T, Sonoki T. Severe aplastic anemia after COVID-19 mRNA vaccination: Causality or coincidence? *J Autoimmun*. 2022; 126: 102782.
14. Woo S, Kim B, Lee SC, Kim MS, Yoon YA, Choi YJ. Very severe immune aplastic anemia after mRNA vaccination against COVID-19 responds well to immunosuppressive therapy: clinical characteristics and comparison to previous reports. *Hematol Amst Neth*. 2022; 27(1): 1191-5.
15. Chen CY, Chen TT, Hsieh CY, Lien MY, Yeh SP, Chen CC. Case reports of management of aplastic anemia after COVID-19 vaccination: a single institute experience in Taiwan. *Int J Hematol*. 2023; 117(1): 149-52.
16. Page MJ, McKenzie JE, Bossuyt PM, Boutron I, Hoffmann TC, Mulrow CD, et al. The PRISMA 2020 statement: an updated guideline for reporting systematic reviews. *BMJ*. 2021; 372: n71.
17. Rethlefsen ML, Kirtley S, Waffenschmidt S, Ayala AP, Moher D, Page MJ, et al. PRISMA-S: an extension to the PRISMA Statement for Reporting Literature Searches in Systematic Reviews. *Syst Rev*. 2021; 10(1): 39.
18. Lockwood C, Munn Z, Porritt K. Qualitative research synthesis: methodological guidance for systematic reviewers utilizing meta-aggregation. *Int J Evid Based Healthc*. 2015; 13(3): 179-87.
19. Cecchi N, Giannotta JA, Barcellini W, Fattizzo B. A case of severe aplastic anaemia after SARS-CoV-2 vaccination. *Br J Haematol*. 2022; 196(6): 1334-6.
20. Wang X, Laczko D, Caponetti GC, Rabatin S, Babushok DV. Severe aplastic anaemia after serial vaccinations for SARS-CoV-2, pneumococcus and seasonal influenza. *EJHaem*. 2022; 3(3): 983-8.
21. Sridhara S, Nair R, Stanek M. Severe Aplastic Anemia After Receiving SARS-CoV-2 Moderna mRNA Vaccination. *J Hematol*. 2022; 11(1): 34-9.
22. Fazlollahi A, Zahmatyar M, Noori M, Nejadghaderi SA, Sullman MJM, Shekarriz-Foumani R, et al. Cardiac complications following mRNA COVID-19 vaccines: A systematic review of case reports and case series. *Rev Med Virol*. 2022; 32(4): e2318.
23. Mingot-Castellano ME, Butta N, Canaro M, Gómez del Castillo Solano M del C, Sánchez-González B, Jiménez-Bárceñas R, et al. COVID-19 Vaccines and Autoimmune Hematologic Disorders. *Vaccines*. 2022; 10(6): 961.
24. Fatima Z, Reece BRA, Moore JS, Means RT. Autoimmune Hemolytic Anemia After mRNA COVID Vaccine. *J Investig Med High Impact Case Rep*. 2022; 10: 23247096211073256.
25. Gadi SRV, Brunker PAR, Al-Samkari H, Sykes DB, Saff RR, Lo J, et al. Severe autoimmune hemolytic anemia following receipt of SARS-CoV-2 mRNA vaccine. *Transfusion (Paris)*. 2021; 61(11): 3267-71.
26. Hidaka D, Ogasawara R, Sugimura S, Fujii F, Kojima K, Nagai J, et al. New-onset Evans syndrome associated with systemic lupus erythematosus after BNT162b2 mRNA COVID-19 vaccination. *Int J Hematol*. 2022; 115(3): 424-7.
27. Rysava R, Peiskerova M, Tesar V, Benes J, Kment M, Szilágyi Á, et al. Atypical hemolytic uremic syndrome triggered by mRNA vaccination against SARS-CoV-2: Case report. *Front Immunol*. 2022; 13: 1001366.
28. Kouhpayeh H, Ansari H. Adverse events following COVID-19 vaccination: A systematic review and meta-analysis. *Int Immunopharmacol*. 2022; 109: 108906.
29. Angelini P, Kavadas F, Sharma N, Richardson SE, Tipples G, Roifman C, et al. APLASTIC ANEMIA

FOLLOWING VARICELLA VACCINE. *Pediatr Infect Dis J.* 2009; 28(8): 746.

30. Donnini I, Scappini B, Guidi S, Longo G, Bosi A. Acquired severe aplastic anemia after H1N1 influenza virus vaccination successfully treated with allogeneic bone marrow transplantation. *Ann Hematol.* 2012; 91(3): 475-6.

31. Röth A, Bertram S, Schroeder T, Haverkamp T, Voigt S, Holtkamp C, et al. Acquired aplastic anemia following SARS-CoV-2 vaccination. *Eur J Haematol.* 2022; 109(2): 186-94.