

Massive Splenomegaly: A Rare Presentation of Megaloblastic Anemia

Tahereh Gholipur-Shahraki¹, Alireza Sadeghi², Padideh Oghab³, Pegah Farrokhi¹, Azadeh Moghaddas¹

¹Department of Clinical Pharmacy, Isfahan University of Medical Sciences, Isfahan, Iran

²Department of Internal Medicine, Faculty of Medicine, Isfahan University of Medical Sciences, Isfahan, Iran

³Department of Oncology and Hematology, Isfahan University of Medical Sciences, Isfahan, Iran

Corresponding Author: Azadeh Moghaddas, Department of Clinical Pharmacy, Isfahan University of Medical Sciences, Isfahan, Iran

Tel/Fax: +983137927074

Email: moghaddas@pharm.mui.ac.ir

Received: 23, Nov, 2019

Accepted: 14, Dec, 2019

ABSTRACT

Megaloblastic anemia is a common disorder with various manifestations. Of the many causes, cobalamin or folate deficiency can eventuate into megaloblastic anemia. It can lead to pancytopenia and mild to moderate splenomegaly, but massive splenomegaly rarely seen in this situation. We describe a 39-year-old woman with marked enlargement of the spleen and pancytopenia that was found to have megaloblastic anemia. The splenomegaly and blood count resolved 4 months after initiation of vitamin B₁₂ therapy. It is important to know massive splenomegaly may occur in megaloblastic anemia, and although it is rare, but can reversible with early treatment.

Keywords: Megaloblastic anemia; Splenomegaly; Vitamin B₁₂

Case presentation

In March 2019, a 39-year-old woman was referred by her general physician to the hospital due to progressive fatigue, weakness, fever, and laboratory finding of pancytopenia from 1 month ago. She was not taking any medication. Her past medical and family history was noncontributory and she hasn't any allergic history.

Pertinent finding of physical examination included a pale patient with muscle weakness and ataxia. The spleen was palpable and she has left upper quadrant pain and tenderness. Her temperature was 37.5°C, blood pressure was 144/90 mmHg with a heart rate of 85/min. The tongue wasn't pale and smooth, which are signs of vitamin B₁₂ deficiency. Other physical examinations were unremarkable.

On first evaluation, her significant laboratory findings included the following: white blood cell (WBC) count of $1.2 \times 10^9/L$, hemoglobin of 4.8 g/dl, mean corpuscular volume (MCV) 96.7 fL, red cell distribution width (RDW) 23.9%, and platelet count of $41 \times 10^9/L$. Liver function tests and creatinine were normal. Results of abdomen ultrasonography and computed tomography (CT) scan were compatible with splenomegaly in which the measured size of spleen was about 17.3 cm in both graphic evaluations.

Because of these findings, she was suspected for acute leukemia and peripheral blood smear. Furthermore, bone marrow examination was performed to differentiate the diagnosis. Smear of her peripheral blood revealed hypochromic and moderate anisopoikilocytosis red cells as well as

teardrop and scattered red blood cells (RBC). Also, moderate leukopenia and severe thrombocytopenia were seen. The bone marrow aspiration and biopsy showed trilineage hematopoiesis with progressive maturation. Fenestration in erythroid precursor and giant metamyelocyte were also reported. Myeloid: erythroid ratio was 1:2 due to severe erythroid hyperplasia with mild dyserythropoiesis. In addition, iron storage in bone marrow samples were decreased and no malignant infiltration in the bone marrow was detected. (Figure 1)

Serum B12 level was 299 (normal 193-982 pg/ml) and folic acid level was 21.9 (normal).

A diagnosis of megaloblastic anemia was made according to signs, symptoms, and laboratory findings. She was treated with parenteral doses of vitamin B12 1000 µg/week for 1 month followed by 1000 µg monthly in company with folic acid 1mg/day. She was followed for 4 months with monthly blood cell count examination shown improvement in leukocytes and platelets after 2 months and hemoglobin level after 3 months. Besides, ultrasonography examination after 4-month treatment revealed a noticeable decrease in splenic size to 9 cm.

Informed consent was signed by the patient and the study protocol was approved by the local Ethics Committee of Isfahan University of Medical Sciences.

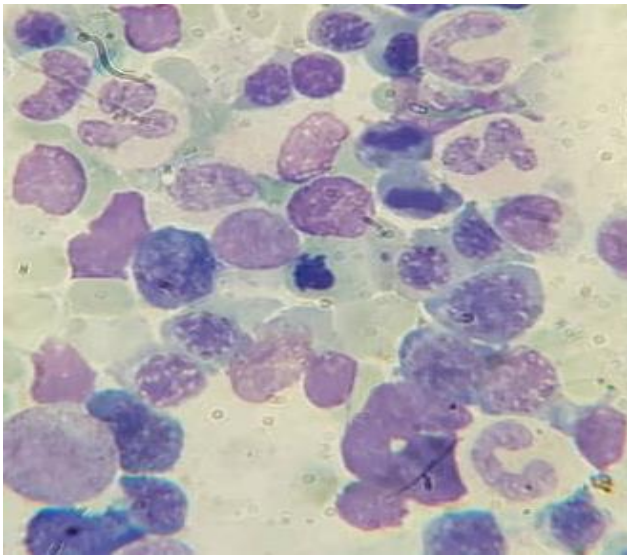


Figure 1. Peripheral blood smear showing macrocytosis and hypersegmented polymorphs

DISCUSSION

Megaloblastic anemia is usually associated with vitamin B12 deficiency and has multiple manifestations⁷. Deficiency of vitamin B12 can result in decreased supply or increased requirement⁸. Measurement of serum level of vitamin B12 may not be reliable as a falsely low level may be observed in patients with multiple myeloma, folic acid deficiency, and pregnancy, also a falsely normal level can be seen in a patient with renal or liver disease, myeloproliferative disorders as well as malabsorption^{4,9}.

However, a vitamin B12 blood level more than 300 ng/L is consistent with other blood disorders and a vitamin B12 blood level below 150 ng/l shows deficiency⁹. Other uncommon causes of megaloblastic anemia include certain drugs that participate in DNA synthesis likewise some inherited disorders².

Clinical effects of megaloblastic anemia can involve various organ systems^{4,5} and may present with severe pancytopenia as can be seen with acute leukemia, but it should be noted that not all patients are symptomatic and only about 67 percent of B12 deficient patients may have abnormalities in their laboratory findings^{2,10}.

One of the known presentations of megaloblastic anemia is splenomegaly, which can occur due to the detaining of a large number of macrocytic RBCs⁶. Size of spleen in megaloblastic anemia-induced splenomegaly is usually between 3 to 14 cm, considered mild to moderate¹¹, while massive splenomegaly is rarely seen in megaloblastic anemia and it was noted in only a few literatures¹²⁻¹⁴. *Halfdanarson et al.*¹² described a 46-year-old woman with severe pancytopenia who has massive splenomegaly and the spleen size reduced after treatment of megaloblastic anemia. In another case reported by *Behera et al.*¹⁴ There are some similar cases with massive spleen due to megaloblastic anemia in a 32-year-old man whose spleen size regressed after vitamin B12 deficiency treatment. Additionally, two infants with severe vitamin B12 deficiency and hepatosplenomegaly and pancytopenia manifestation were recently reported¹³.

In all similar cases leukolymphoblastic anemia and signs of anisopoikilocytosis at peripheral blood smear were noted similar to our mentioned patient. Massive splenomegaly caused by other reasons such as bacterial infections, hairy cell leukemia, chronic lymphoblastic leukemia should be considered for differential diagnosis in similar cases.

In our patient, hematologic, clinical, laboratory evaluation as well as patient's clinical condition was compatible with megaloblastic anemia and the patient were completely recovered by vitamin B12 and folic acid supplementation. Furthermore, massive splenomegaly should be considered as a rare clinical presentation of megaloblastic anemia.

CONCLUSION

In conclusion, we described a 39-year-old woman presented with pancytopenia and massive splenomegaly while her level of vitamin B12 was normal but her peripheral blood smear, bone marrow aspiration and biopsy were compatible with megaloblastic anemia. She was successfully treated by vitamin B12 and folic acid supplementation. Subsequently, laboratory findings and spleen size were recovered. Megaloblastic anemia has a complex presentation and even could be mistaken by acute leukemia symptom, furthermore, it should consider as megaloblastic anemia's differential diagnosis. Since the megaloblastic anemia is easily curable, health care professions should undertake all efforts to identify this disorder as soon as possible to prevent complications due to pancytopenia and splenomegaly.

CONFLICT OF INTEREST

All authors declare that they have no conflict of interest.

REFERENCES

1. Aslinia F, Mazza JJ, Yale SH. Megaloblastic anemia and other causes of macrocytosis. *Clin Med Res*. 2006 Sep;4(3):236-41.. 2006;4(3):236-41.
2. Wickramasinghe SN. Diagnosis of megaloblastic anaemias. *Blood Rev*. 2006;20(6):299-318.
3. Maktouf C, Bchir A, Louzir H, et al. Megaloblastic anemia in North Africa. *Haematologica*. 2006;91(7):990-1.
4. Langan RC, Zawistoski KJ. Update on vitamin B12 deficiency. *Am Fam Physician* . 2011 15;83(12):1425-30.
5. Stabler SP. Clinical practice. Vitamin B12 deficiency. *N Engl J Med*. 2013;368(2):149-60.
6. Jameson JL, Kasper DL, Longo DL, Fauci AS, Hauser SL, Loscalzo J. *Harrison's principles of internal medicine*, 20th edn. New York: McGraw-Hill Education, 2018
7. Wintrobe MM, Greer JP. *Wintrobe's clinical hematology*, 13th edn. Philadelphia, Pennsylvania : Lippincott Williams & Wilkins, 2014.
8. Rojas Hernandez CM, Oo TH. Advances in mechanisms, diagnosis, and treatment of pernicious anemia. *Discov Med* . 2015;19(104):159-68.
9. Klee GG. Cobalamin and folate evaluation: measurement of methylmalonic acid and homocysteine vs vitamin B(12) and folate. *Clin Chem* . 2000;46(8 Pt 2):1277-83.
10. Andres E, Affenberger S, Zimmer J, et al. Current hematological findings in cobalamin deficiency. A study of 201 consecutive patients with documented cobalamin deficiency. *Clin Lab Haematol* . 2006;28(1):50-6.
11. Bezerra AS, D'Ippolito G, Faintuch S, et al. Determination of splenomegaly by CT: is there a place for a single measurement?. *AJR Am J Roentgenol* . 2005;184(5):1510-3.
12. Halfdanarson TR, Walker JA, Litzow MR, et al. Severe vitamin B12 deficiency resulting in pancytopenia, splenomegaly and leukoerythroblastosis. *Eur J Haematol* . 2008;80(5):448-51.
13. Belen B, Hismi BO, Kocak U. Severe vitamin B12 deficiency with pancytopenia, hepatosplenomegaly and leukoerythroblastosis in two Syrian refugee infants: a challenge to differentiate from acute leukaemia. *BMJ Case Rep* . 2014;2014:bcr2014203742.
14. Behera V, Randive M, Sharma P, et al. Megaloblastic anemia presenting with massive reversible splenomegaly. *Indian J Hematol Blood Transfus* . 2015;31(2):297-9.