

Covid-19 and Thrombotic Thrombocytopenic Purpura: A Case Report

Maryam Darnahal¹, Hamed Azhdari Tehrani¹, Mohammad Vaezi², Shirin Haghighi¹

¹Department of Hematology and Medical Oncology, Shahid Beheshti University of Medical Sciences, Tehran, Iran

²Hematology, Oncology and Stem Cell Transplantation Research Center, Tehran University of Medical Sciences, Tehran, Iran

Corresponding Author: Shirin Haghighi, Department of Hematology and Medical Oncology, Shahid Beheshti University of Medical Sciences, Tehran, Iran

Tel: 00989123261197

E-mail: Shirinhaghighi1346@gmail.com

Received: 26, Oct, 2020

Accepted: 21, Nov, 2020

ABSTRACT

Endothelial injury by toxins, drugs, immune complexes leads to activation of coagulation cascade and thrombosis, which result in platelet consumption and red blood cell injury. These thrombotic microangiopathies can potentially injure numerous organs and result in organ dysfunction. In this case, we present the fourth reported patient with thrombotic thrombocytopenic purpura associated with COVID-19.

Keywords: Covid-19; Thrombotic thrombocytopenic turpura (TTP); Plasma exchange

Case presentation

A 56-year-old woman with a previous history of locally advanced breast cancer (Locally advanced ER-/PR-/HER2+ breast cancer treated as adjuvant therapy, which was under follow-up) was admitted to our hospital for respiratory symptoms. She was febrile and dyspneic. Laboratory data showed Bicytopenia (WBC: 14600/ μ l with PMN dominancy, Hb: 6 mg/dl and PLT: 41000/ μ l). LDH was increased (2245 U/L). Coagulation tests were normal. Total Bilirubin and direct Bilirubin were 10.5 mg/dl and 0.8 mg/dl, respectively. Retic count was 8%. Coombs antibodies were negative. In peripheral blood smear, numerous schistocytes (10% in each field) were found. These findings raised the concern for thrombotic microangiopathic anemia (TMA); therefore, ADAMTS13 activity, antigen level and antibody were requested.

Lung CT-Scan revealed patchy infiltration consistent with COVID-19 (Figure 1). Nasopharyngeal COVID-19

PCR was positive after 48 hours. ADAMTS-13 activity was low (0.01 IU/ml with the normal range of 0.4-1.3) and its antibody was high (36.2 U/ml with a positive range more than 15), so COVID-19 associated with TTP was confirmed. Other autoimmune disorders associated with TTP such as rheumatologic disorders and viral infections such as hepatitis and HIV were screened and all were negative.

We started plasma exchange with fresh frozen plasma 30 cc/kg/daily from the beginning in the emergency department. Dexamethasone and Interferon-Beta were started at a dose of 12 mg daily and 1.2 million units every other day, respectively. Plasma exchange continued in subsequent days; however, platelet count and hemoglobin did not change specifically despite improvement in respiratory symptoms and patient general condition. We intensified the plasma exchange program twice a day but nothing changed.

Copyright © 2021 Tehran University of Medical Sciences. This work is licensed under a Creative Commons Attribution-Noncommercial 4.0 International license (<http://creativecommons.org/licenses/by-nc/4.0>). Non-commercial uses of the work are permitted, provided the original work is properly cited.

Regarding plasma exchange refractoriness, Rituximab at a dose of 375mg/m² started weekly for 4 subsequent weeks and plasma exchange continued in the same way as before.

After 3 days of Rituximab administration, the patient's level of consciousness began to decrease and she became lethargic. Brain CT-Scan showed left frontal lobe hemorrhage without any midline shift (Figure 2). CBC showed WBC 18500/ μ l, Hb 9.5 mg/dl and PLT 58000/ μ l. In consultation with Neurosurgery service, they recommended close monitoring of the size and expansion of hemorrhage. The patient intubated and went on a ventilator. We continued plasma exchange and supportive care about 2 weeks, after that the platelet count reached 155000/ μ l and the LDH level became normal (356 IU/ml). Unfortunately severe lung involvement and hemorrhagic CVA resulted in death and resuscitation did not rescue her life.

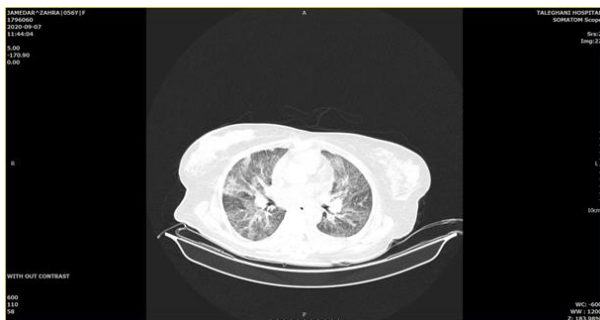


Figure 1: Lung CT-Scan showing bilateral and diffuse infiltration pneumonia

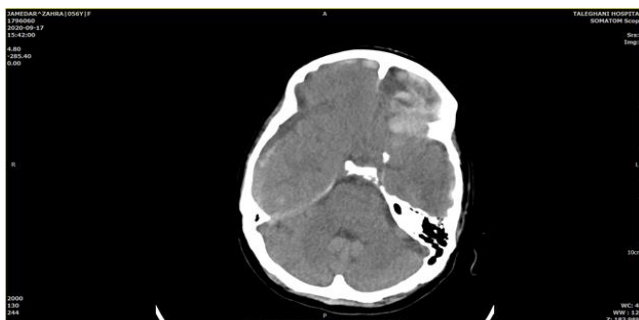

Figure 2: Hemorrhagic CVA in left frontal lobe

DISCUSSION

At the end of 2019, Corona virus emerged as a worldwide issue¹. Soon, it became pandemic and millions of people with different manifestations affected^{2,3}. However, there are some issues about increasing thrombogenicity through different mechanisms such as activating coagulation factors, decreasing vitamin K level and serious illness leading to disruption of the endothelial barrier. Endothelial injury can be caused by several triggers such as toxins, infections, and drugs⁴. The latter causes thrombotic microangiopathic anemia with both manifestations of hemolytic anemia and thrombocytopenia leading to serious end-organ damage⁵. There are a lot of mechanisms that cause thrombotic microangiopathic anemia such as infection, drugs, and pregnancy after allogenic HSCT⁶. This is the third case report of TTP associated with COVID-19 infection and the second case in our hospital⁷⁻⁸. In this case, we had to administer Rituximab as an immunosuppressive agent and because of the long onset of action we continued plasma exchange until this drug took effect. Although all TMA in all of the four case reports occurred in women, more studies are required to indicate that TMA prevalence may be associated with gender.

Ethical approval

All procedures performed in this study were in accordance with the ethical standards of the Helsinki declaration.

CONFLICT OF INTEREST

The authors declare that they have no conflict of interest.

REFERENCES

1. Zhu N, Zhang D, Wang W, et al. China Novel Coronavirus Investigating and Research Team. A Novel Coronavirus from Patients with Pneumonia in China, 2019. *N Engl J Med.* 2020; 382(8):727-733.
2. Chan JF, Yuan S, Kok KH, et al. A familial cluster of pneumonia associated with the 2019 novel coronavirus indicating person-to-person transmission: a study of a family cluster. *Lancet.* 2020; 395(10223):514-523.
3. Chen R, Liang W, Jiang M, et al. Medical Treatment Expert Group for COVID-19. Risk factors of fatal outcome

- in hospitalized subjects with coronavirus disease 2019 from a nationwide analysis in China. *Chest*. 2020; 158(1):97-105.
4. George JN, Nester CM, McIntosh JJ. Syndromes of thrombotic microangiopathy associated with pregnancy. *Hematology Am Soc Hematol Educ Program*. 2015; 2015:644-8.
 5. Fakhouri F, Vercel C, Frémeaux-Bacchi V. Obstetric nephrology: AKI and thrombotic microangiopathies in pregnancy. *Clin J Am Soc Nephrol*. 2012; 7(12):2100-6.
 6. Guan WJ, Ni ZY, Hu Y, et al. China Medical Treatment Expert Group for Covid-19. Clinical Characteristics of Coronavirus Disease 2019 in China. *N Engl J Med*. 2020; 382(18):1708-1720.
 7. Albiol N, Awol R, Martino R. Autoimmune thrombotic thrombocytopenic purpura (TTP) associated with COVID-19. *Ann Hematol*. 2020; 99(7):1673-1674.
 8. Hindilerden F, Yonal-Hindilerden I, Akar E, et al. Covid-19 associated autoimmune thrombotic thrombocytopenic purpura: Report of a case. *Thromb Res*. 2020; 195:136-138.