

A Survey of 121 patients with Idiopathic Thrombocytopenic Purpura

Shahriariahmadi* A., Tahmasian M.

¹Department of Hematology–Oncology, Taleghani Hospital, Kermanshah University of Medical Science, Iran

*Corresponding author: Email: masoud_tahmsian@yahoo.com

Abstract

Introduction: Idiopathic Thrombocytopenic Purpura is one of the most common causes of thrombocytopenia with various clinical courses and different responses to its treatment modalities. Therefore, we decided to evaluate the clinical course of this disease in our patients.

Methods: In this case series study, from March 1998 to March 2004, we evaluated 121 patients. As a first line of treatment, all of those patients received prednisolone (1mg/kg/day) for 6 weeks. Those who didn't respond or were refractory to prednisolone were candidates for splenectomy, and those who refused these modalities or didn't respond to them were treated with Azathioprine.

Results: 99 patients (81.8%) were female and 22 (18.2%) were male, aged 11-73 years (mean; 28.6). Two patients had immune hemolytic anemia in addition to thrombocytopenia, 4 had systemic lupus erythematosus, and one was HIV positive. %44.6 of patients fully responded to prednisolone, 42 patients (%34.7) underwent splenectomy and %83.3 of them responded to it. 31 splenectomies were performed in the first three months after diagnosis and 27 (87.1%) of them showed complete response, but 8 (72.7%) of the patients splenectomized after 3 months, had complete response. 14 patients were treated with Azathioprine, 2 of which (14.3%) platelet count normalized.

Conclusion: ITP is more common in females than males. Prednisolone is preferred as a non-invasive treatment with suitable response in comparison to other modalities responses to splenectomy, indicating that this modality of treatment is useful and effective, especially when performed in the first 3 months of the diseases.

Key words: Idiopathic thrombocytopenic purpura (ITP), Prednisolone, Splenectomy, Azathioprine

Received: 10, Dec., 2004

Accepted: 22, Jan., 2005

Introduction

Idiopathic thrombocytopenic purpura (ITP) is an acquired hemorrhagic disease in which autoantibodies to platelets cause their sequestration and destruction by mononuclear macrophages, principally in the spleen. If increased production of platelets by megakaryocytes doesn't compensate for platelet destruction, the number of circulating platelets decreases (thrombocytopenia), resulting in a characteristic bleeding tendency (purpura).^(1,2)

In this disease, bleedings from mucous membranes and intracranial hemorrhage were also seen.^(3,4) Prevalence of ITP is 1/10,000.⁽⁵⁾ Acute ITP is common in children and accounts for 90% of the pediatric cases of immunologic thrombocytopeniae. It is a self-limiting, often post-viral disease.^(3,6) While most children with the disease experience a relatively short and benign clinical course, ITP in adults often lasts more than 6 months (chronic ITP) and is resis-

tant to conventional treatment (corticosteroids, splenectomy, immunosuppressive agents, intravenous immunoglobulin (IVIG) cytotoxic chemotherapy, bone marrow transplantation, etc.^(1,7) The goal of medical management is to increase the platelet count to a safe level, without the risks of bacterial infections associated with splenectomy or toxicity from prolonged corticosteroid therapy.⁽¹⁾ In order to determine clinical course, outcome, and trends in management, we decided to study patients with ITP at Taleghani Hospital in Kermanshah.

Methods

In this "case series" study, in which 121 patients were evaluated from March 1998 to March 2004, diagnosis was based on history, physical examination, complete blood cell count and bone marrow study. All of these patients required treatment because of platelet count less than 20,000/ μ l or hemorrhagic mani-

Table- 1: Clinical presentations of patients on first visit.

Clinical presentation of patients	NO	Percent
Asymtomatic	18 cases	14.8%
Petechia , Purpura & Ecchymosis	92 cases	76.8%
Epistaxis & Gingival Bleeding	8 cases	6.6%
Menometrorrhagia	5 cases	4.1%
GI Bleeding	2cases	1.6%
Intracranial Hemorrhage	1 case	0.8%

festations such as mucosal bleeding or cutaneous purpura regardless of platelet count. We started treatment with prednisolone (1 mg/Kg/day) and after response (normalization of platelet count), dose of prednisolone was tapered off slowly within 6 weeks. In patients with no response to prednisolone, in corticosteroid dependent patients, or those who relapsed after discontinuation of treatment, splenectomy was considered. Patients who didn't respond to splenectomy and had symptomatic thrombocytopenia or platelet count under 20,000/ μ l were treated with Azathioprine (2-3 mg/kg/day).

Results

121 patients were evaluated in this study: 99 (81.8%) women and 22(18.2%) men, mean age 28.6 (11-73) years old (Fig-1). 14.9% were asymptomatic at presentation, the mean presenting platelet count was 26000/ μ l (7000-50000). In symptomatic patients the most common symptoms were purpura, ecchymosis and lower frequency mucosal bleeding (Table-1).

In 9 to 81 months follow-up period, one patient was HIV positive, one had hyperthyroidism, 11 cases were ANA positive in 4 of whom,

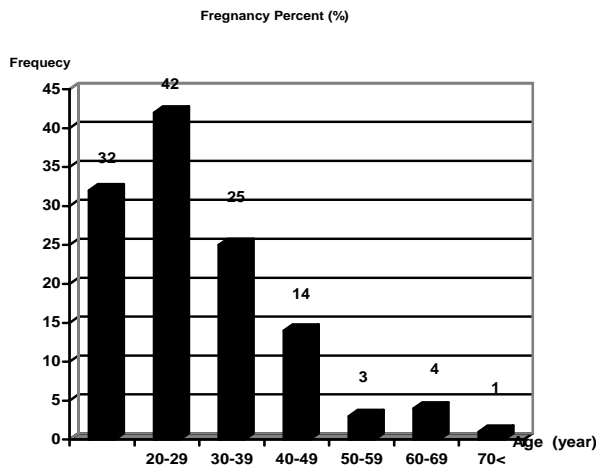


Fig -1: Age distribution of patients with ITP

Table- 2: Other diseases or conditions in combination with ITP

ANA positive	11 cases	9.0%
SLE	4 cases	3.3%
Autoimmune Hemolytic Anemia	2 cases	1.6%
HIV positive	1case	0.8%
Hyperthyroidism	1case	0.8%

other manifestations of systemic lupus erythematosus appeared in later follow-ups; 2 patients had immune hemolytic anemia combined with thrombocytopenia (Table -2).

54 patients (44.6%) had complete and sustained response to prednisolone. In 7 patients (5.8%), platelet count showed no increase in response to prednisolone.

In 34 cases (28.1%) response to prednisolone was not adequate and in another 26 cases (21.5%) platelet count decreased after discontinuation of prednisolone despite primary response (Table-3).

54 patients were designated for splenectomy, but 12 (9.9%) refused splenectomy despite platelet counts less than 20000/ μ L.They were given azathioprine. 42 patients (34.7%) were splenectomized and in 35 cases (83.3%), platelet count normalized just after splenectomy.

In 5 cases, platelet count didn't show sufficient increase and in another 2 patients, platelet count remained less than 20,000/ μ l despite splenectomy. In 42 splenectomized cases, 31 splenectomies were performed in the first three months after diagnosis (early splenectomy) of which 27 (87.1%) showed good response. 11 Patients had late splenectomy (after three months as from diagnosis) of which 8 (72.7%) had good response. All patients who were designated for splenectomy received pneumovax before surgery and 8 of them received IVIG because of platelet counts less than 10,000/ μ l.

Finally, 14 patients (11.5%) were treated with Azathioprine, in 2 cases of whom (14.3%) platelet count became normal, 9 cases (64.3%) showed relative response and 3 patients (21.4%) didn't show any response to Azathioprine. Therefore, only 3 patients (2.5%) showed no response to all the treatment protocols. Un-

Table-3: Kinds of responses to Corticosteroid

Kind of responses	No	Percent
Complete sustained response	54	44.6
Relative response	34	28.1
Corticosteroid dependency	26	21.6
Without response	7	5.8
Total	121	100

fortunately two of our patients died, one man because of cerebral astrocytoma (4 months after splenectomy) and one woman because of septicemia (13 months after splenectomy).

Discussion

The appropriate management of ITP is still controversial. The incidence and course of the disease are different in children and adults and, within these groups, newborns and pregnant women have specific needs for treatment.⁽⁸⁾ Yet, there is little unanimity regarding how and when to treat even the most severe cases. In this study, the majority of patients (81.8%) were female with a female to male ratio of 4.5:1. In another study, the ratio was 1.9:1.⁽⁹⁾ ITP in adults is principally a disease of young women.⁽¹⁰⁾ The highest age frequency (34.7%) in our study was between 20-29 years. 14.9% of our patients were asymptomatic at presentation and treated for platelet count less than 20,000/ μ l. In another study, 21.8% of patients were asymptomatic.⁽²⁾

The goal of medical management is to increase the platelet count to a safe level, without risk of bacterial infections associated with splenectomy or toxicity from prolonged corticosteroid therapy.⁽¹⁾ Several clinical studies have shown that Corticosteroids may shorten the time of platelet count recovery.^(2,11,12,13) In our study, 44.6% attained absolute remission, similar to another researches.^(2,9) Dose of prednisolone in our study was 1mg/kg/day(although, low dose of prednisolone (0.5 mg/kg/day) may be as effective as the conventional dose⁽⁹⁾.) However corticosteroid therapy as a first line of treatment makes good response.

As a second line of treatment, splenectomy was accomplished. Splenectomy provides a high frequency of durable response for adult patients with ITP.^(14,16) In our study 34.7% of cases were splenectomized and 83.3% showed complete response in early follow up. In other studies response to splenectomy has been 65-70% in long duration follow-ups (2.6, 14).

Our findings confirmed that early splenectomy (during the first three months after diagnosis) has better results than late splenectomy (87.1% versus 72.7%).

Also, hematological results after laparoscopic splenectomy is comparable to open splenectomy⁽¹⁵⁾, but all of our patients underwent open

splenectomy. We don't have early mortality as a complication of splenectomy, but one of our patients (2.4%) died of septicemia 13 month after splenectomy.

New agents and modalities such as Intravenous Rh immunoglobulin (IV RhIG), Rituximab, Anti CD20 monoclonal antibodies and Bone marrow transplantation demonstrate the capability of improving outcome and decreasing toxicity^(7,17). These agents should be reserved for symptomatic thrombocytopenia if refractory to current treatments.^(7,17) We didn't use them in our patients. In our study, 11.5% of patients received Azathioprine, but only 14.3% of them achieved complete response, 64.3% had relative response and 21.4% didn't show any response. In several studies, 5.2% or 10.3% of ITP patients had another autoimmune disease such as autoimmune hemolytic anemia or autoimmune neutropenia.^(2,11)

According to our study, 11 patients (9.1%) were ANA positive, in 4 of whom (3.3%) other manifestations, like SLE appeared. And 2 cases (1.7%) had autoimmune hemolytic anemia. Although one of the complications of AIDS was ITP, only one of our patients (0.8%) was HIV positive and he is under treatment now.

Although the basic underlying pathophysiology of ITP has been known for more than 50 years, current treatment guidelines are based on expert appraisal rather than being evidence-based because of a lack of high quality clinical trial and research.⁽¹⁸⁾

References

1. Sandler SG, Review: Immune thrombocytopenic purpura: an update for immuno hematologists. *Immunohematol* 2004; 20(2): 112-117.
2. Wong GC, Lee LH. A study of idiopathic thrombocytopenic purpura (ITP) patients over a ten- year period. *Ann Acad Med singapor* 1998; 27(6): 789-793.
3. Handin R, Disorders of the platelet and vessel wall. In: Braunwald E, Fauci A, kasper D etal. *Harrison's principles of internal medicine*. PA: MCGraw –Hill; 2005:746.
4. Bussell J, Cines D: Immune thrombocytopenic purpura, Neonatal Alloimmune thrombocytopenia and post transfusion purpura In: Hoffman R, Benz EJ, Furie B et al. *Hematology Basic Principle and practice*. PA: Churchill Livingstone 2000; 2096.
5. Diagnosis and treatment of idiopathic thrombocytopenic purpura: recommendation of the american society of hematology. *Annual of internal medicine* 126(4): 319-326.
6. Gills S. The thrombocytopenic purpura recognition and management. *Drugs* 1996; 51(6): 942-953

7. Sandler SG, Tutuncyglu SO. Immune thrombocytopenic purpura –Current management practices. *Expert Opin Pharmacother* 2004; 5(12): 2515-2527.
8. George JN, Raskob GE. Clinical decisions in idiopathic thrombocytopenic purpura. *Hosp Pract (offed)* 1997; 32(9): 159-160, 163-166, 169-170.
9. Bedri A, Abebe E. Idiopathic thrombocytopenic purpura (ITP)in Ethiopian children : clinical findings and response to therapy. *Ethiop Med J* 1995; 33(2): 75-81.
10. George JN, Raskob GE. Idiopathic thrombocytopenia purpura: diagnosis and managment. *Am J Med Sci* 1998; 316(2):87-93.
11. Michel M, Chanet V, Galicier L et al. Autoimmune thrombocytopenic purpura and common variable immunodeficiency: analysis of 21 cases and review of the literature. *Medicine (Baltimor)* 2004; 83(4): 254-263.
12. Ohmine K, Izumi T, Muriok et al. Low –dose prednisolone therapy for idiopathic thrombocytopenic purpura. *Rinsho ketsueki* 2000; 41(1):8-11.
13. Jackson N, Mustapha M, Baba AA. Adult idiopathic thrombocytopenic purpura without the option of splenectomy. *Med J Malaysia* 1995; 50(3): 250-255.
14. Kojouri K, Vesely SK, Terrell DR et al. Splenectomy for adult patients with idiopathic thrombocytopenic purpura: a systematic review to assess long-term platelet count response, prediction of response and surgical complications. *Blood* 2004; 104(9): 2623-2634.
15. Berends FJ, Schep N, Cuesta MA et al. Hematological long-term results of laparoscopic splenectomy for patients with idiopathic thrombocytopenic purpura: a case control study. *Surg Endosc* 2004; 18(5): 766-770.
16. Ismet A , Irfan K, Emin K et al. Splenectomy results in patients with idiopathic thrombocytopenic: 10 years of experience in Turgut ozal Medical Center. *Clin lab Hematol* 2004; 26(3): 211-2147.
17. Vesely SK, Perdue JJ, Rizvi MA et al. Management of adult patients with persistent idiopathic thrombocytopenic purpura following splenectomy: a systemic review. *Ann Intern Med* 2004; 140(2): 112-120.
18. Stasi R, Provan D. Management of immune thrombocytopenic purpura in adults. *Mayo clin Pro* 2004; 79(4):504-522.

Note: Hereby we want to apologize to our recorders for the mistitled article on page 37 No. a of IJHOBMT by the author Dr. *Ali Shahriariahmedi* and coworkers. The correct title reads as follows: **Primary Bilateral Adrenal Lymphoma: A case report**