

Visceral Leishmaniasis Presented as Myelofibrosis and Low grade lymphoma in a Sporadic Region of Iran, Report a Rare Case

Gholamreza Toogeh,¹ Reza Shirkoohi,² Manouchehr keyhani,¹ Mehdi Nickbin,³ Safa Najafi,¹ Maryam Salimi,¹ Leila Farsi,⁴ Shirin Ferdowsi⁵

¹Hematology-Oncology and BMT Research Center, Imam Khomeini Hospital, Tehran University of Medical Sciences, Tehran, Iran

²Molecular Genetics, Cancer Research Center, Cancer Institute, Imam Khomeini Hospital Complex, Tehran University of Medical Sciences, Tehran, Iran

³Department of Infectious Diseases, Pasargad Hospital, Tehran, Iran

⁴Physiology Department, Basic Sciences Ward, Gonabad University of Medical Sciences, Gonabad, Iran

⁵Hematology Department, Basic Sciences Ward, Gonabad University of Medical Sciences, Gonabad, Iran

Corresponding Author: Shirin Ferdowsi, M.Sc

Department of Basic Sciences, Gonabad University of Medical Sciences, Gonabad, Iran

Tel: +98 0533 7225027

E-mail: ferdowsishirin@gmail.com

Abstract

We describe a case of leishmaniasis in a 55-year-old male who presented with weakness, fever and anemia. The patient was born and lived all his life in Talaghan, a non-endemic region of kala-azar and there was no history of travel to endemic region for leishmania. In primary diagnosis, the patient suspect has been myelofibrosis and then lymphoma and underwent chemotherapy. His general condition worsened and bone marrow biopsy was performed again and leishmania promastigotes seen in the bone marrow. Specific identification of the parasite was done by RAPD-PCR. After two weeks of treatment, he was transferred to ICU due to heart attack and after 4 days he died due to aortic valve ABE.

Keywords: Visceral leishmaniasis, Myelofibrosis, Low grade lymphoma, Sporadic region

Introduction

Visceral leishmaniasis (VL), known also as Kala-azar, is a chronic infectious disease caused by a protozoan parasite of the genus leishmania; it is transmitted by fly bite.(1) The most highly endemic areas of VL in Iran are parts of Fars and Bushehr Provinces in the south, the districts of Meshkinshahr and Moghan in northwest, and Qom Province in central Iran. Other parts of Iran are considered as sporadic areas for VL. Visceral leishmaniasis is common (over 98%) among children under 12 years old in different endemic foci in Iran and adult cases frequently present with subclinical and asymptomatic forms in endemic regions.(2, 3) In Iran, the visceral form is mainly due to *Leishmania infantum*.(3) and the main reservoir of this parasite is infected dogs.(4) Delay and difficulty in

diagnosis are common, especially at its early stage of the disease.(5) Here we present a case of visceral leishmaniasis in which the patient was misdiagnosed as myelofibrosis and low grade lymphoma from sporadic region.

Case report

A 55-year-old man who was a resident of Talaghan, an non-endemic region of visceral leishmaniasis in central of Iran, was admitted to the Department of Hematology in Imam Khomeini Hospital affiliated to Tehran University of Medical Sciences in January 2007 with the presentation of weakness, fever, weight loss and anemia. The case was suspected to have myelofibrosis and underwent splentomy in the other center 7 months before admission to this hospital. Despite of treatment, the

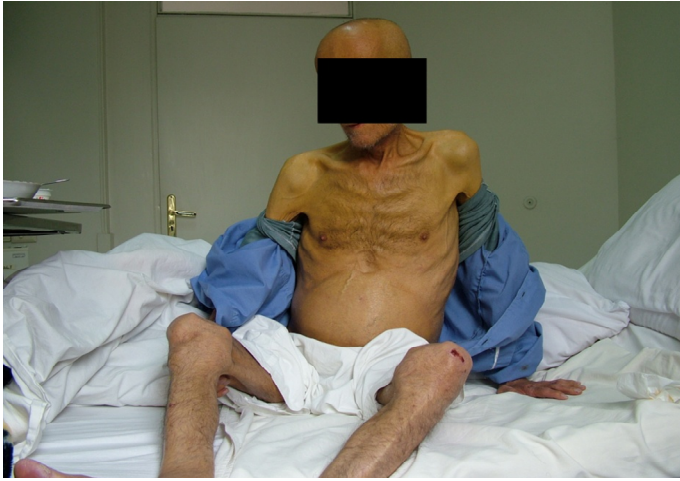

Figure- 1. The patient on admission.

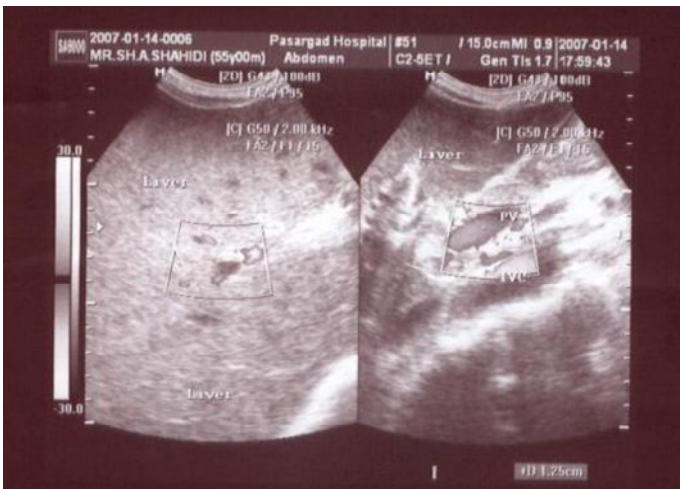

Figure- 2. The liver sonography.

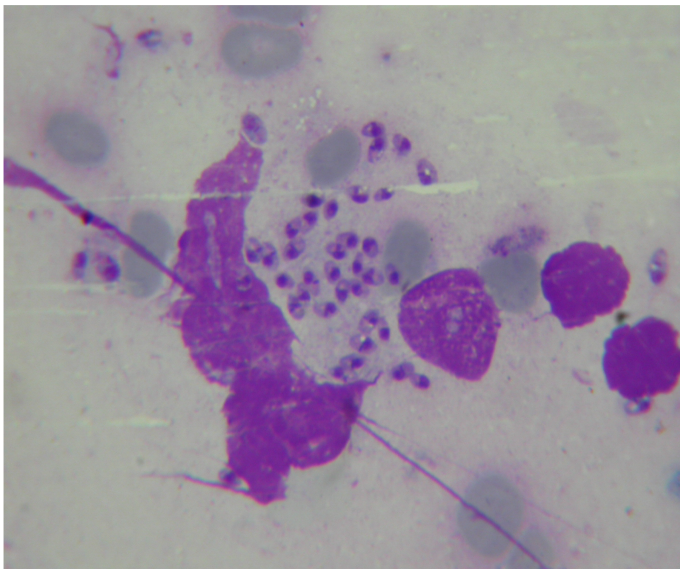


Figure- 3. An aspiration smear stained with Giemsa revealing plenty of Leishmania amastigotes.

patient's symptoms were progressing. On admission patient was complaining abdominal pain and diarrhea and his physical examination on abdomen showed an enlarged liver, ascites and evidence of splenectomy (Figures- 1, 2). Laboratory findings were as follows: hemoglobin 11.5 g/dl; hematocrit 36%; platelet count $100 \times 10^9/L$, and

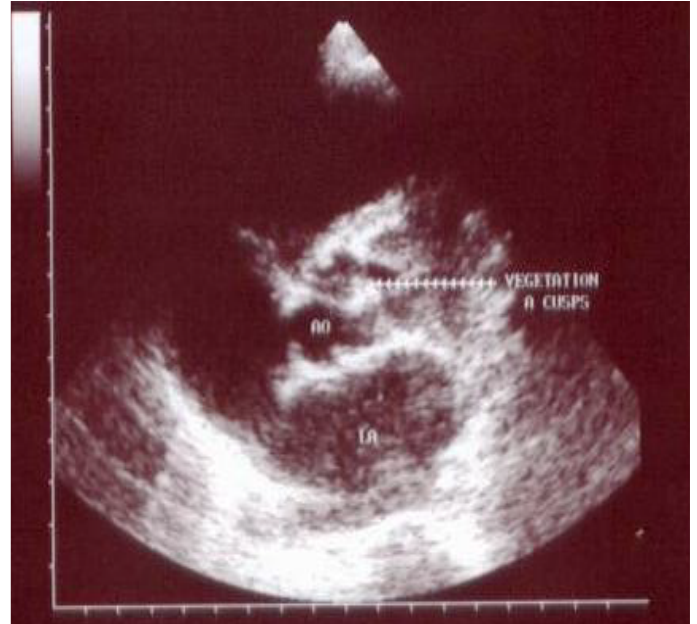

Figure- 4. Patient's echocardiography.

white blood cells (WBCs) $9.9 \times 10^9/L$. Liver enzymes revealed lactate dehydrogenase (LDH) 542 u/l, SGPT (ALT) 20 u/l, SGOT (AST) 64 u/l, alkaline phosphatase 579 u/l, total bilirubin 2.6 mg/dl, and direct bilirubin 2 mg/dl. Additional blood tests showed triglycerides of 326 mg/dl, Fasting Blood Sugar 133 mg/dl, and Blood Urea Nitrogen 36 mg/dl. Diagnostic tests such as hepatitis B, hepatitis C, tuberculosis (TB), HIV, and serological testing for leishmania antibodies were performed and they were negative. Urine and stool examination revealed no significant pathology and peripheral blood smear was negative for microorganism. Patient was repeatedly suffered from weight loss, so that patient weight was 40 Kg. Bone marrow biopsy was performed and a diagnosis of lymphoma was suspected. After 4 weeks his general condition worsened and bone marrow biopsy was performed again and leishmania promastigotes seen in the bone marrow.(Figure- 3) Leishmania promastigotes were analyzed by RAPD-PCR technique and type infantum were reported. However there was no history of travel to endemic region for leishmania or insect bite. All past pathologic preparations were thoroughly reviewed, including bone marrow examinations and liver biopsy. Liver biopsy revealed Leishmania parasites.

After definitive diagnosis of leishmania, treatment was initiated with pentavalent antimony 20 ml/kg daily. It was accompanied with gradual improvement in clinical condition of the patient, and the body temperature returned to the normal value after the seventh day of treatment. The patient was well on discharge. After two weeks he

presented with cough and weakness. Patient was febrile; the temperature was 39°C, and a severe hypotension that did not respond to dopamine. Patient was transferred to ICU due to heart attack and alteration in orientation level which caused to coma. Blood culture was positive for staphylococcus and after 4 days he died due to aortic valve ABE. (Figure- 4)

Discussion

There are three important endemic region of VL in Iran: Ardebil, East Azerbaijan, and Fars provinces, and some sporadic region.(6) During 1998– 2006, approximately 2,056 cases of VL were reported in Iran, and Ardabil Province contained approximately 30.4% of the cases. More than 90% of VL cases are reported in the pediatric age group and is usually characterized by prolonged fever, hepatosplenomegaly, reversed albumin-to-globulin ratio and proteinuria.(7, 8) The first case of visceral leishmaniasis in Iran was reported by Pouya in Mazandaran Province during 1949.(9) Visceral leishmaniasis (VL) or kala-azar caused by *L. donovani*, *L. infantum*, *L. chagasi*, *L. amazonensis* and rarely *L. tropica* minor.(10) In humans, *L. infantum* causes a wide spectrum of clinical manifestations, from asymptomatic or oligosymptomatic infection to acute or chronic disease.(11)

Previous case reports indicate that visceral leishmaniasis can be misdiagnosed as myeloma,(12, 13) mixed cryoglobulinaemia(14) malignant lymphoma,(15) lymphoblastic leukemia,(16) and autoimmune hepatitis(17). Rocha(18) reported that the bone marrow fibrosis is transient (pseudomyelofibrosis) in human kala-azar and these patients are expected to show regression after treatment. Therefore the presence of associated myelofibrosis it could easily have been mistaken for chronic idiopathic myelofibrosis. Our case was a 55-year-old man living in Talaghan, central Iran, and a non-endemic region of kala-azar. In primary diagnosis, the patient suspect has been myelofibrosis and then lymphoma.

The diagnosis depends on serological studies or direct parasite detection.(19) Spleen biopsy is reported diagnostic of VL in over 95% of cases, liver biopsy and bone marrow sensitivity is reported to be about 70% .In general, serology is not reported to be a very useful test in both visceral and cutaneous leishmaniasis as it may give false positive as well as false negative results.(20) Gagnaire reported that the *Leishmania* serological test and bone marrow examination included in the

work-up may be initially negative, necessitating repeated bone marrow procedures for diagnosis.(22) Serology test was negative in this case. In addition, bone marrow biopsy was performed during admission and leishmania diagnosed on the third bone marrow aspirate (after two previous negative examinations). He was born and lived all his life in Talaghan and there was no history of travel to endemic region for leishmania and he denied having been bitten by insects. Several studies suggest that infection by *L. infantum* can exist in a subclinical form in healthy individuals without a previous background of cutaneous or visceral leishmaniasis and those with asymptomatic infection can act as reservoirs for parasites.(2, 23, 24) So it is speculated that he was infected by asymptomatic individuals. Several results have been reported that the undertaken chemo therapy may weaken the immunity system leading to a viscerotropic infection.(25, 26) Bacterial infections are often seen in patients with visceral leishmaniasis and *Pseudomonas aeruginosa* and *Staphylococcus aureus* are the most common agents.(27) In this case, the patient's age, an initially negative assay for *Leishmania*, living in sporadic region and no history of presence in endemic areas caused the disease undiagnosed. After suspicion to lymphoma, treatment with chemotherapy undermines the immune system and disease progression. Blood culture was positive for staphylococcus and patient died due to aortic valve ABE that is one of the major complications of leishmania.

Conclusion

Early detection of the infection is necessary in order to start effective treatment and prevent more serious complications. Therefore the clinical presentation should be considered in the differential diagnosis of malignant neoplasms.

Acknowledgment

We would like to thank Hematology-Oncology and BMT Research Center, Imam Khomeini Hospital for assistance in providing sample and patient information.

References

1. Desjeux P. Human leishmaniasis: epidemiology and public health aspect. *World Health Stat Q* 1992;45:267–75.
2. Mohebbali M, Hajjaran H, Hamzavi Y, Mobedi I, Arshi Sh, Zarei Z, Akhoundi B, Naeini K, Manouchehri AR, Fakhar M .Epidemiological

- aspects of canine visceral leishmaniasis in the Islamic Republic of Iran. *Vet Parasitol* 2005;129:243–252
3. Edrissian Gh H, Nadim A, Alborzi AV, Ardehali S. Visceral leishmaniasis: the Iranian experiences. *Arch Iran Med* 1999 ;1:22–26
 4. Mohebbali, M., Poormohammadi, B., Kanani, A. Gerbillidae and Cricetidae, other animal hosts of visceral leishmaniasis in Meshkin-shahr district of Iran. *East Mediterranean Health J* 1998; 4; 234–238.
 5. Cohen D, Fields S. CT findings in visceral leishmaniasis mimicking lymphoma. *Comput Med Imaging Graph* 1988;12:325–7.
 6. Rassi Y, Kaverizadeh F, Javadian E, Mohebbali M. First report on natural promastigote infection of *Phlebotomus caucasicus* in a new focus visceral leishmaniasis in north west Iran. *Iran J Public Health* 2004; 33: 70–72.
 7. Mohebbali M, Hamzavi Y, Edrissian GH, Forouzani A. Seroepidemiological study of visceral leishmaniasis among humans and animal reservoirs in Bushehr province, Islamic Republic of Iran. *Eastern Mediterranean Health J* 2001;7: 912–917.
 8. Kohanteb J, Ardehali SM, Rezai HR: Detection of *Leishmania donovani* soluble antigen and antibody in the urine of visceral leishmaniasis patients. *Trans R Soc Trop Med Hyg* 1987; 81: 578–580.
 9. Pouya, Y. Study of visceral leishmaniasis in Gilan and Mazandaran provinces of Iran. *J. Med. Fac. Tehran* 1949; 7, 359–361.
 10. Pearson R, De Queiroz Sousa A, Jeronimo S. *Leishmania* species: visceral (kala-azar), cutaneous, and mucosal leishmaniasis. In: Mandell G L, Bennett J E, Dolin R, editors. *Mandell, Douglas and Bennett's Principles and Practice of Infectious Diseases*. Philadelphia: Churchill Livingstone; 2000. p. 2831 /45.
 11. D'Oliveira Jr, A., Costa, S., Barbosa, A., Orge, M. & Carvalho, E. Asymptomatic *Leishmania chagasi* infection in relatives and neighbors of patients with visceral leishmaniasis. *Memo'rias do Instituto Oswaldo Cruz*, 1997;92 :15–20.
 12. Garcia-Menendez L, Santamaria Lopez C, Fernandez Eroles AL, Megido Lahera M, Galende del Canto J, Aguilera Sanz C. Monoclonal component in visceral leishmaniasis: a rare association that can lead to misdiagnosis. *Rev Clin Esp* 1998;198:517-20.
 13. Gabrielli GB, Zaia B, Stanzial AM, Corrocher R. Visceral leishmaniasis: a rarely diagnosed disease in northern Italy. Report of a case. *Ann Ital Med Int* 2001;16:185-91.
 14. Casato M, De Rosa FG, Pucillo LP, et al. Mixed cryoglobulinemia secondary to visceral leishmaniasis. *Arthritis Rheum* 1999;42:2007-11 .
 15. Kavakami A, Fukunaga T, Usui M, et al. Visceral leishmaniasis misdiagnosed as malignant lymphoma. *Intern Med* 1996;35:434-5.
 16. Jones SG, Forman KM, Clark D, Myers B. Visceral leishmaniasis misdiagnosed as probable acute lymphoblastic leukaemia. *Hosp Med* 2003;64:308–309
 17. Dalgic B, Dursun I, Akyol G. A case of visceral leishmaniasis misdiagnosed as Autoimmune hepatitis. *Turk J Gastroenterol* 2005;16:52–53
 18. Rocha Filho FD, Ferreira FV, Mendes Fde O, Ferreira FN, Karbage A, Alencar ML, et al. Bone marrow fibrosis (pseudo-myelofibrosis) in human kala-azar. *Rev Soc Bras Med Trop* 2000;33:363-6.
 19. Berman JD: Human leishmaniasis: Clinical, diagnostic, and chemotherapeutic developments in the last 10 years. *Clin Infect Dis* 1997;24:684-703
 20. Bryceson A.D.M. Leishmaniasis. In *Manson's Tropical Diseases*. 20th ed. (WB Saunders Company Ltd)1996; 1213-1242
 21. Gagnaire MH, Galambrun C, Stephan JL. Hemophagocytic syndrome: A misleading complication of visceral leishmaniasis in children--A series of 12 cases. *Pediatrics* 2000;106(4):E58.
 22. Badaro R, Jones TC, Carvalho EM, Sampaio D, Reed SG, Barral A, Teixeira R, Johnson WD Jr. New perspectives on a subclinical form of visceral leishmaniasis. *Journal of Infectious Diseases* 1986; 154:1003–1011.
 23. Costa CH, Stewart JM, Gomes RB, Garcez LM, Ramos PK, Bozza M, Satoskar A, Dissanayake S, Santos RS, Silva MR, Shaw JJ, David JR, Maguire JH. Asymptomatic human carriers of *Leishmania chagasi*. *Am J Trop Med Hyg.* 2002; 66(4):334-7.
 24. Garcia-Cordoba F, Ortuño FJ, Segovia M, Gonzalez Diaz G. Fatal visceral leishmaniasis, with massive bone-marrow infection, in an immunosuppressed but HIV-negative Spanish patient, after the initiation of treatment with meglumine antimoniate. *Ann Trop Med Parasitol* 2005; 99:125–130
 25. Pittalis S, Nicastrì E, Spinazzola F, Ghirga P, De Marco M, Paglia MG, Narciso P. *Leishmania infantum* leishmaniasis in corticosteroid--treated patients. *BMC Infect Dis* 2006; 6:177
 26. Andrade TM, Carvalho EM, Rocha H. Bacterial infections in patients with visceral leishmaniasis. *J Infect Dis.* 1990 ;162(6):1354-9.