

Primary hyperaldosteronism as initial presentation of adrenal cortical carcinoma with liver metastasis: a case report

Naser Aghamohammadzadeh¹, Afsaneh Faraji², Farshid Bozorgi³, Ismail Faraji⁴, Majid Moghadaszadeh⁵

¹Assistant Professor, Endocrinology Department, Tabriz University of Medical Sciences, Tabriz, Iran.

²Medical Student, Student Research Committee, Tabriz University of Medical Sciences, Tabriz, Iran.

³Anatomical and Clinical Pathologist, Tabriz University of Medical Sciences, Tabriz, Iran.

⁴Internist, fellow of Endocrinology, Tabriz University of Medical Sciences, Tabriz, Iran.

⁵Resident of Internal Medicine, Tabriz University of Medical Sciences, Tabriz, Iran.

Corresponding author: Majid Moghadaszadeh, MD

Internal Medicine Department, Tabriz University of Medical Sciences, Tabriz, Iran.

E-mail: m_moghadaszadeh@hotmail.com

Tel: +989144141359

Abstract

Adrenocortical carcinoma (ACC) is a rare tumor and usually a fatal disease which can develop at any age in either sex. Differential diagnosis between malignant and benign adrenal mass is not easy which leads to significant clinical challenge for optimal treatment. Here we report a 22-year-old woman diagnosed with primary hyper aldosteronism initially but disease relapsed during six months and magnetic resonance imaging revealed tumor with metastasis to the liver.

Key words: Adrenocortical carcinoma, Liver metastases, Surgery.

Received: 10, Jan, 2013

Accepted: 6, Feb, 2013

Introduction

Adrenal cortical carcinoma (ACC) is a very rare heterogeneous tumor which represents 0.02% all neoplasias and its global estimated incidence is 0.5-2 per every 1000,000 persons each year¹. There is a bimodal age distribution with two peaks in the first and fourth to fifth decades^{2, 3}. Its etiology is unknown. The majority of cases are incidental diagnosis of advanced stage disease with metastases. Tumors of adrenal gland are classified as functioning and non-functioning tumors. Functional tumors occur in 59.3%-62% of cases and they may produce cortisol (30%-40%), androgens (20%-30%), estrogens (6%-10%) or aldosterone (2%-2.5%) and mixed pattern of hormone production is seen in 24%-35% of patients^{2, 4, 6}. This hormone production may trigger patient's symptoms; and they depend on patient's age and on which hormones are over produced. Although it is potentially curable at early stages, only about 30% of these malignancies are confined to the adrenal gland when they are diagnosed, because these tumors tend to be found years after they began growing, they have opportunity for near and distant metastases and this aggressive behavior leads to its poor prognosis. The most common

sites of distant metastases are the liver (48%-85%), lung (30%-60%), lymph nodes (7%-20%) and bone (7%-13%)^{4, 7, 8}. We present a case of functioning adrenal cortical carcinoma in a 22-year-old female patient with liver metastases and a retroperitoneal mass which recurred after right adrenal surgical resection during six months. In the article, the symptoms associated with hormones produced by the tumor, diagnostics and treatment with regard to the progression of disease have also been discussed.

Case report

A 22-year-old female patient with a 4-month history of weakness and tachycardia referred to Imam Reza hospital in Tabriz because of intensity of symptoms and loss of consciousness. The blood examination revealed decreased levels of potassium; 2.7 mEq/L and her blood pressure was 190/100 mmHg, she just received emergency agents as outpatient. After three months, symptoms flared up and the patient was admitted to the department of internal medicine. A detailed past medical history of the patient was taken; hypertension during last six months and preeclampsia in her prior pregnancy were detected. No family

history of malignancies found. In her review of systems; weight loss (7kg during last four months), weakness, headache, tachycardia, nocturia, polyuria, polydipsia and frequency were found and there was no significant history of abdominal pain, vomiting, urinary incontinence or fever. Mucosal dehydration and positive trousseau test were points in general and physical examination. Before hospitalization she obtained Atenolol 50mg/24h for hypertension. Liver and renal function tests, complete blood count and urine 24h analysis were within normal limits. Urine complete examination was negative for albumin and sugar, and in microscopic analysis; WBC: 15-16 and epithelial cell: 27-28 was reported, No crystals or casts were detected and urine culture was negative. Serum potassium was 2.9mEq/L and serum Ca ion was 0.87mmol/L. Arterial blood gas examination indicated metabolic alkalosis (PH=7.54, PCO₂=34.7, HCO₃=29). ECG and chest x-ray were normal. Blood measurements of plasma aldosterone and rennin after one hour upright standing posture in the morning were: aldosterone=350 units, rennin=0.9 units. A Captopril Suppression Test (CST) did not result in aldosterone suppression. In order to confirm the first diagnosis, an abdominal spiral computed tomography was performed but there was no evidence of any lesions in liver, kidneys and adrenal glands. Despite the previous oral and later intravenous potassium supplementation of up to 40mEq/24h, potassium level was low and on the 10th day of hospitalization it was 3.2mEq/L. Calcium channel blockers, β -blockers and potassium sparing diuretics were added to the treatment and resulted in blood pressure decrease to 140/80mmHg on the last day of hospitalization. The patient was discharged from hospital but symptoms recurred after a week. In magnetic resonance imaging (MRI) of adrenal glands with IV contrast, a mass measuring 53×25×46 mm in size at the posterior aspect of inferior vena cava and medial side of liver just above right adrenal gland confirmed an adrenal gland tumor (Fig. 1). The patient underwent exploratory laparotomy with excision of right adrenal gland. The tumor had extended behind IVC, no invasion to adjacent organs or metastasis to lymph nodes was noted during the

operation. Per-operative finding was a mass of about 6×5.5×1.5 cm.

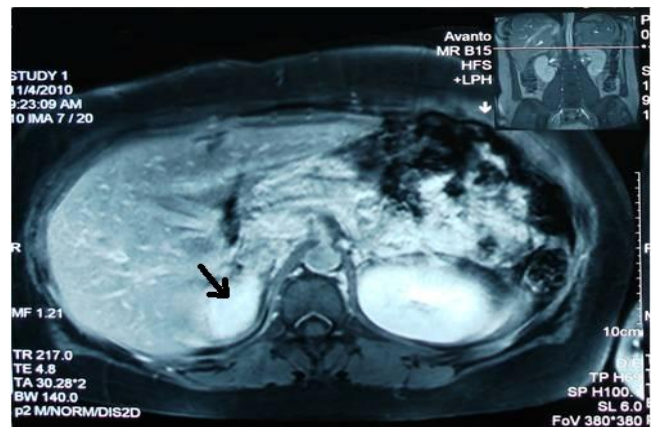


Fig 1. magnetic resonance imaging. Right adrenal mass

Histopathological examination revealed adrenal tissue with a cortical adenoma with areas of hemorrhage and necrosis, composed of cells with granular cytoplasm, mild and focal nuclear pleomorphism and occasional mitosis. After the surgical intervention, she was discharged uneventfully. Then she was followed-up irregularly due to pregnancy. Signs and symptoms have been revealed for six months, until the end of her first trimester (16th week), meanwhile she had flaring of hypertension and hypokalemia during anesthesia for McDonald's operation. Followed-up MRI showed no evidence of recurrent tumor at right side, even size or configuration of left side adrenal gland was normal. Her poor follow-up during pregnancy resulted in recurring hypertension and hypokalemia during cesarean section. On post operative control MRI of abdomen one year after right adrenalectomy, a round solid mass at the site of removed adrenal gland measuring 56×53 mm on diameter was seen. The mass involved the inferior aspect of the liver and probably superior anterior aspect of the right kidney. These findings indicated relapse of the removed adrenal tumor (Fig. 2). Liver needle biopsy was performed and proved liver tissue with relatively normal parenchymal cells and small focus of atypical cells. Primary surgery's slides reviewed; pathological examination revealed a cream-brown mass about 3.5×3 cm with hemorrhagic and necrotic areas. On microscopic assessment, neoplastic proliferation of adrenocortical cells in a diffuse pattern sometimes with severe pleomorphism,

tumor cell necrosis with occasionally mitoses more than 5/50HPF was seen.

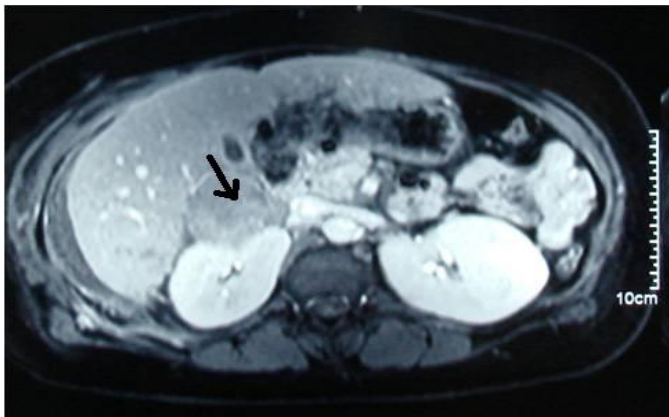


Fig 2. adrenal tumor relapse with liver involvement.

Tumoral cells also invaded the capsule, so according to Weiss criteria for malignancy, (Nine histological criteria of Adrenal Cortical Carcinoma: 1. Nuclear grade C Fuhrman III/I 2. Mitotic rate 5/50 hpf. 3. Abnormal mitosis 4. <25% clear cells 5. 1/3 diffuse architecture 6. Necrosis 7. Venous invasion 8. Sinusoidal invasion 9. Capsular invasion.⁹), this neoplasm had five of nine criteria which was compatible with adrenal cortical carcinoma (Fig. 3 and Fig. 4).

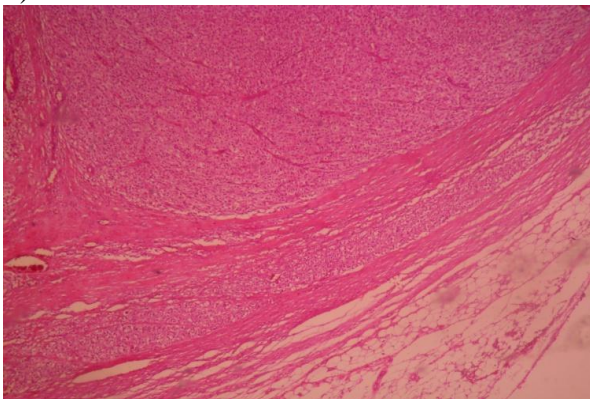


Fig 3. capsular invasion is seen by neoplastic adrenocortical cells

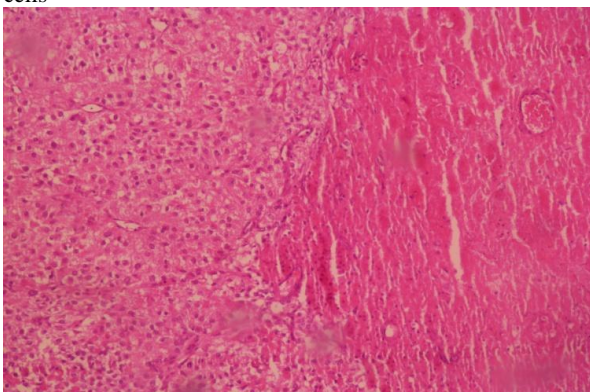


Fig 4. Tumor cell necrosis and diffuse pattern of neoplastic growth

The patient was discussed in tumor board and surgery planned for her followed by adjuvant treatment; surgery versus chemotherapy with Mitotane. The Patient underwent surgery again with resection of right recurring adrenal tumor, liver right lobe segmental lobectomy, cholecystectomy and resection of retroperitoneal mass was done under general anesthesia. Histopathologic assessment of second surgical specimens showed segmental lobectomy of right hepatic lobe (14×12×12 cm) and retroperitoneal mass resection (5×5×4 cm) also showed the same microscopic features of primary adrenal cortical tumor composed of large eosinophilic cells with highly atypical nuclei arranged in peritheliomatous and diffuse pattern with extensive necrosis (Fig. 5 and Fig. 6).

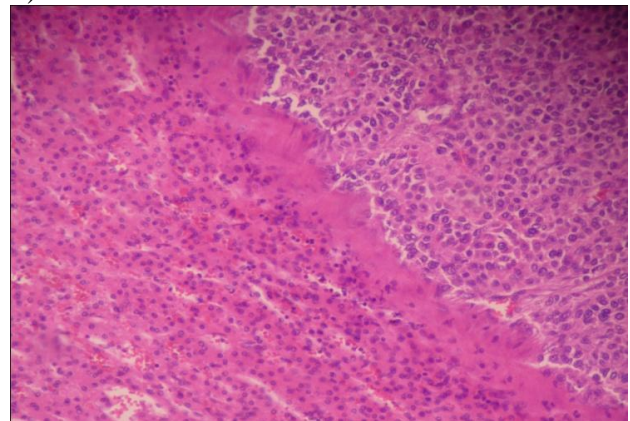


Fig 5. Hepatic tissue infiltrated by neoplastic adrenocortical cells.

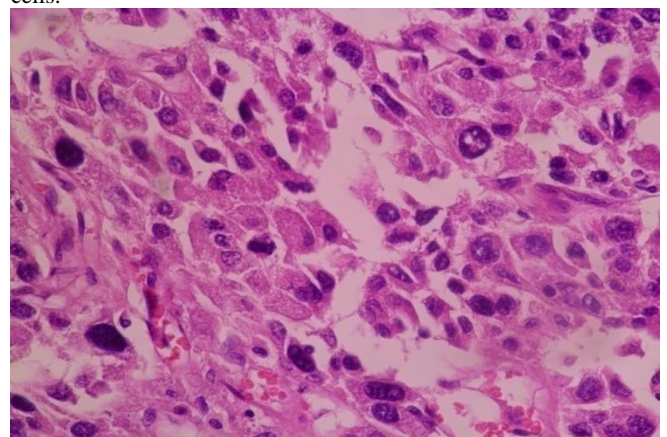


Fig 6. Metastatic neoplasm composed of eosinophilic highly atypical cells

Discussion

We present a case of disseminated ACCs, which is a rare neoplasm occurring with a frequency of 1-2 cases per million per year, and the prevalence has been variably reported at 2 cases per one population per year worldwide, accounting for 0.05% to 0.2% of all cancers¹⁰.

Etiology of adrenal cortical carcinoma is still unclear, but roles of genetic and environmental factors, e.g. pesticide pollution, have been largely considered¹¹. It is more frequent in women (58.6%) than in men (41.4%)¹¹. ACC has poor prognosis and the tumor size is still the best single predictor of prognosis. The recommended imaging exams are computed tomography and Magnetic Resonance (MR), but MR is more sensitive¹², and showed the tumor in our patient. Routine adrenal biopsy is not recommended, because of procedure risk and a limited diagnostic value¹². One review study reported 60% of the tumors as functional tumors¹³ that may secrete excessive glucocorticoids (Cushing's syndrome), mineralocorticoids and their procedures; including androgens (Virilization) or estrogens (Feminization), as well as aldosterone causing hypertension¹⁴. The non-functioning tumors may present with pain or fullness in the abdomen due to mass effect, weight loss, weakness, fever and myalgias¹³, or it may be discovered incidentally during radiographic imagings (CT or MRI) performed for other reasons¹⁵. In rare cases its first manifestations are distant metastases, e.g. to bones, which can cause pathological fractures or bone pain¹⁶. Differentiating between adrenal adenoma and carcinoma in a small lesion can be challenging, although definitive diagnosis of malignancy in adrenocortical lesions is based on the presence of distant metastasis or local invasion¹⁸, due to this problem we made a delayed diagnosis. Clinical staging of the tumor is essential for treatment plan, as well as prognosis determination. For staging tumor, node and metastasis system (TNM) of the American Joint Committee on cancer should be used; a tumor size of 5 cm or less with no spread to surrounding tissues or to lymph nodes without distant metastasis is classified as stage I. A tumor larger than 5 cm with other stage I characteristics is classified as stage II. Tumor invasion to nearby tissues and/or spread to nearby lymph nodes is classified as stage III and distant metastasis is classified as stage IV¹³. Our patient has stage IV disease with a tumor size about 5 cm and distant metastasis to the liver and retroperitoneal mass. Surgery is still the mainstay of treatment for metastatic carcinoma because there is no definitive

protocol for chemotherapy. Although mitotan is still the first choice pharmacological treatment, but its therapeutic value is still very controversial and it has not been proved to be effective¹⁷. It is taken orally (35% to 45% absorption) and it has a long half-life (18-159 days). Nausea, vomiting, anorexia, weight loss, diarrhea, lethargy, sedation, dizziness, ataxia, gynecomastia, leucopenia and reversible growth arrest in children are the common side effects of Mitotan therapy¹⁴. Prednisolon in a daily dose of 5-10 mg is used to alleviate symptoms¹².

Following the surgeries, our patient received approximately 1 to 6 g mitotan per day for period of one month, but mitotan was later discontinued because of gastrointestinal side effect for the patient; including ileus. Now, cancer relapse by liver metastases has influenced our case physically and emotionally and has reduced life-expectancy of patient.

References

1. Kopf D, Goretzki PE, Lehnert H. Clinical management of malignant adrenal tumors. *J Cancer Res Clin Oncol*. 2001; 127: 143-155.
2. Wooten MD, King DK. Adrenal cortical carcinoma. Epidemiology and treatment with mitotane and a review of the literature. *Cancer* 1993;72:3145-55.
3. Stratakis CA, Chrousos GP: Adrenal cancer. *Endocrinol Metab Clin North Am* 2000; 29:15-25.
4. Ng L, Libertino JM. Adrenocortical carcinoma: diagnosis, evaluation and treatment. *J Urol* 2003; 169:5-11.
5. Dackiw AP, Lee JE, Gagel RF, Evans DB. Adrenal cortical carcinoma. *World J Surg* 2001; 25:914-26.
6. Icard P, Chapuis Y, Andreassian B, Bernard A, Proye C. Adrenocortical carcinoma in surgically treated patients: a retrospective study on 156 cases by the French Association of Endocrine Surgery. *Surgery*. 1992; 112:972-979.
7. Schulick RD, Brennan MF. Long-term survival after complete resection and repeat resection in patients with adrenocortical carcinoma. *Ann Surg Oncol* 1999;6:719-
8. Wajchenberg BL, Albergaria Pereira MA, Medonca BB. Adrenocortical carcinoma: clinical and laboratory observations. *Cancer* 2000; 88:711-36.
9. SILVERBERG's principles & practice of surgical pathology & cytopathology, page 2187, volume 2; 2006, C HURCHILL LIVING STONE, ELSEVIER.
10. Norton JA, Le HN. Adrenal tumors. In: DeVita VT, Hellman S, Rosenberg SA, eds. *Cancer: principles and practice of oncology*. 6th ed. Philadelphia, PA: Lippincott Williams & Wilkins; 2000:1770-1771.
11. Szczeklik A, ed. *Choroby wewnętrzne*. Tom 1. Kraków, Medycyna Praktyczna, 2006:1143.
12. Justyna Gil, Marta Kalemekiewicz, Edyta Polak, Marta Kostecka-Matyja. Disseminated

- adrenocortical carcinoma: case report. *Pol Arch Med Wewn.* 2007; 117 (7): 317-321
13. Allolio B, Fassnacht M. Clinical review: Adrenocortical carcinoma: clinical update. *J Clin Endocrinol Metab* 2006; 91:2027-2037.
 14. Sreelatha Chalasani, MD, MPH; Hemender Singh Vats, MD; Tarit K. Banerjee, MD, FACP; and Alan K. McKenzie, MD. Metastatic Virilizing Adrenocortical Carcinoma: A Rare Case of Cure with Surgery and Mitotane Therapy. *Clinical Medicine & Research*, Volume 7, Number 1/2: 48-51
 15. Grumbach MM, Biller BM, Braunstein GD, Campbell KK, Carney JA, Godley PA, Harris EL, Lee JK, Oertel YC, Posner MC, Schlechte JA, Wieand HS. Management of the clinically inapparent adrenal mass ("incidentaloma"). *Ann Intern Med* 2003; 138:424-429.
 16. Kasperlik-Zaluska AA, Migdalska BM, Makowska AM. Incidentally found adrenocortical carcinoma. A study of 21 patients. *Eur J Cancer.* 1988 34, 1721-1724.
 17. Barzon L, Sonino N, Fallo F, et al. Prevalence and natural history of adrenal incidentalomas. *Eur J Endocrinol* 2003; 149:273-85.
 18. Xichun S, Alberto A, Claudia Y. Castro. Adrenal cortical carcinoma with Concomitant Myelolipoma in a Patient with Hyperaldosteronism. *Archives of Pathology and Laboratory Medicine*; 129:6.p144-7